

Appendicular Skeleton

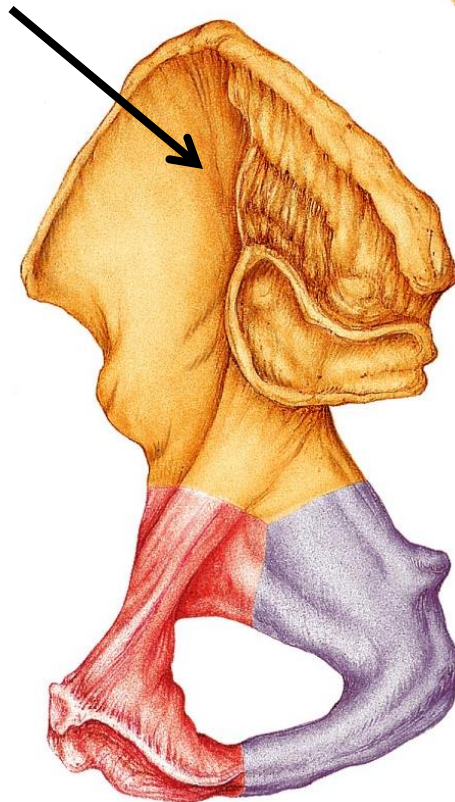
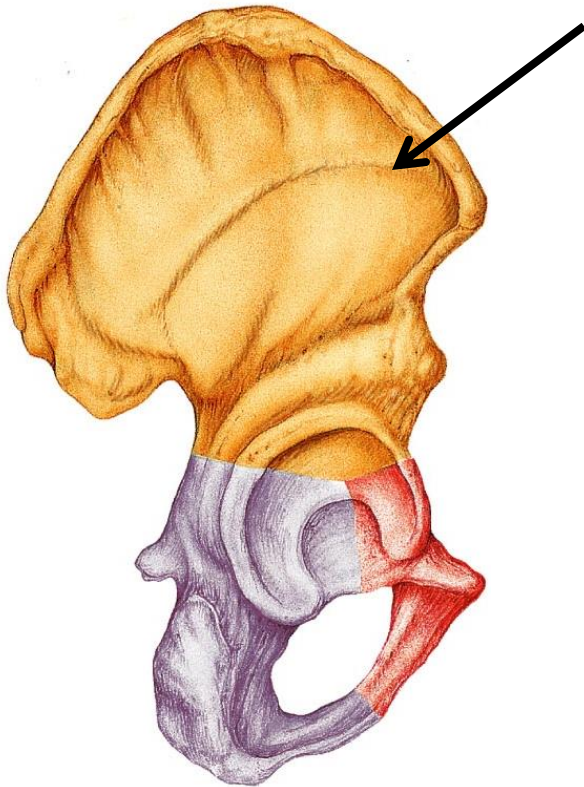
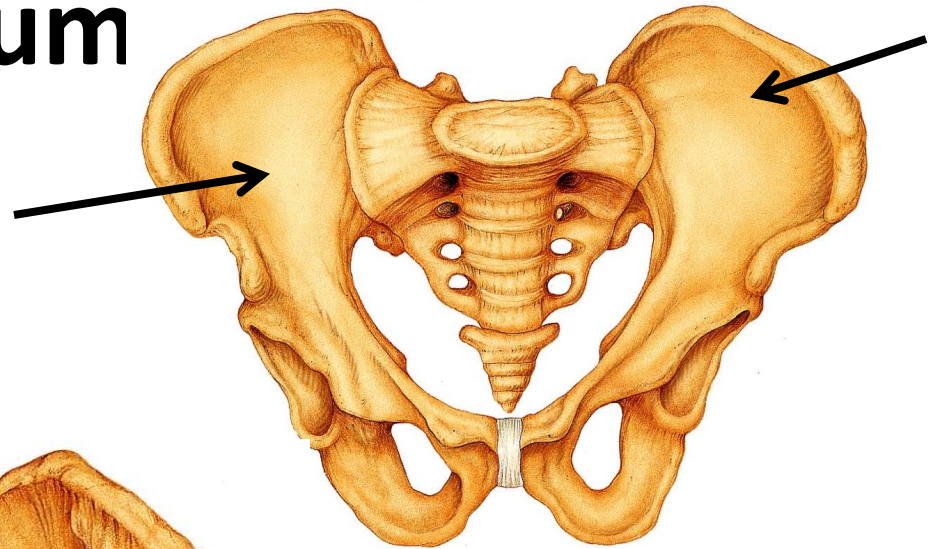
Pelvic Girdle

Pelvic (hip) Girdle

- Two hip bones aka coxal bones or os coxae
 - Fused as adults, separate in children
- Actually three bones:
 - Ilium
 - Ischium
 - Pubis
- Provides a strong stable support for vertebral column and pelvic organs. Also attaches the lower limbs to axial skeleton.

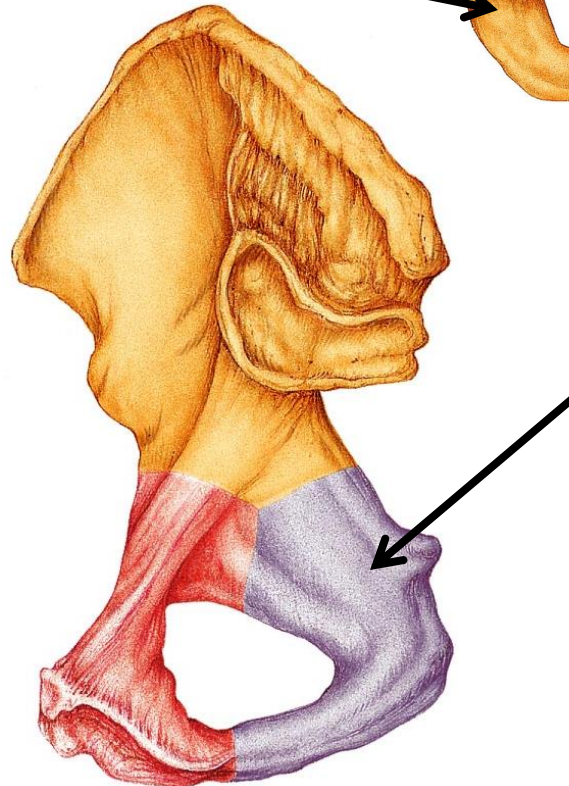
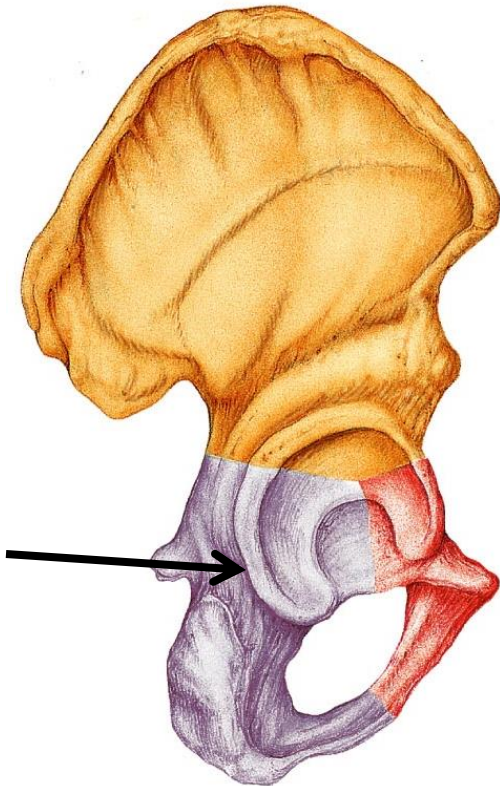
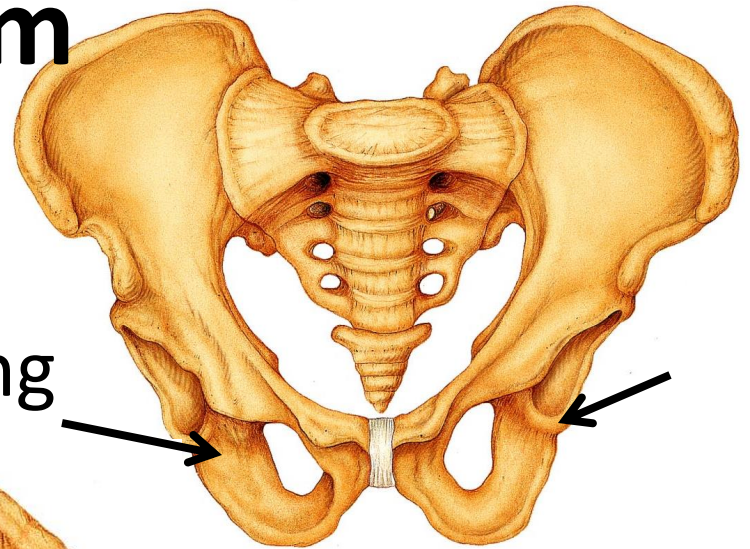
Ilium

- Most superior
- Largest, flaring bone



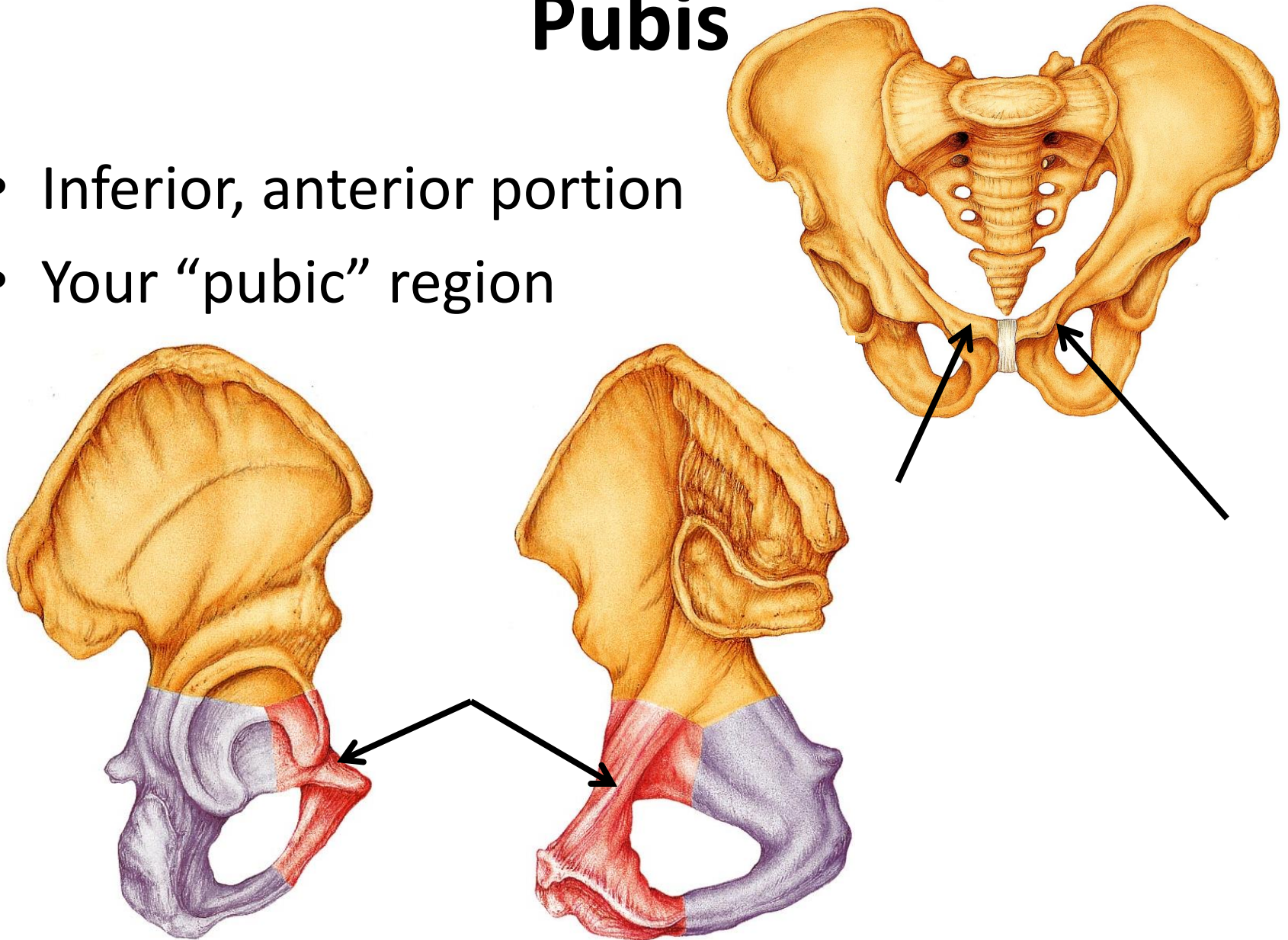
Ischium

- Inferior, posterior portion
- Weight is here when sitting

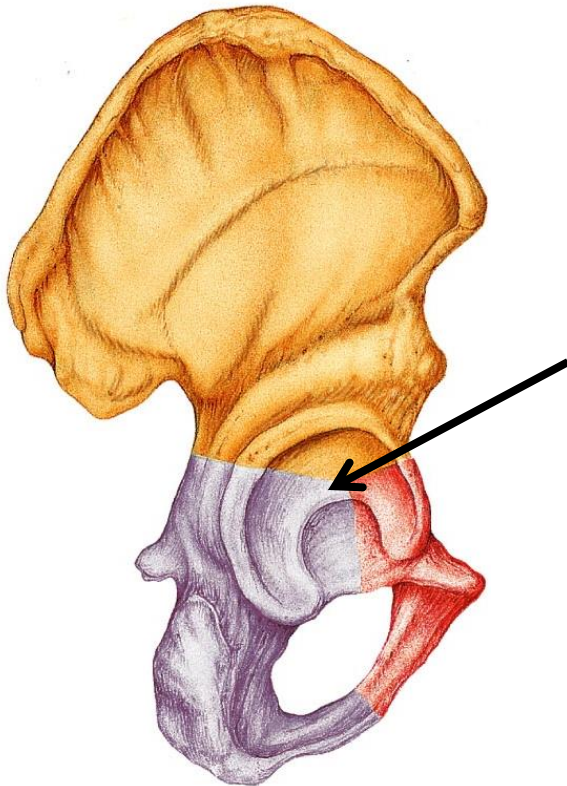
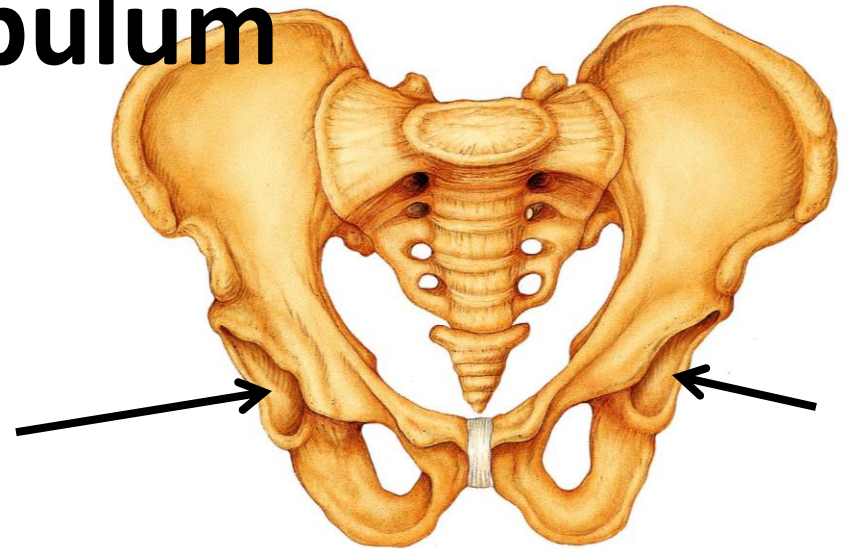


Pubis

- Inferior, anterior portion
- Your “pubic” region



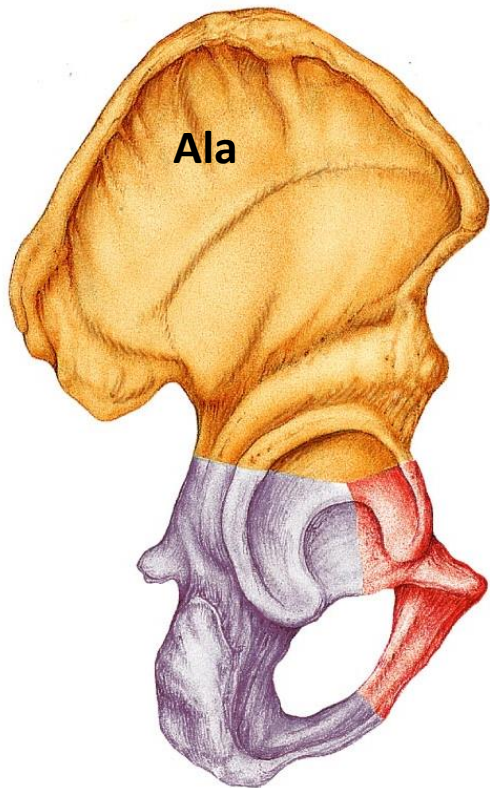
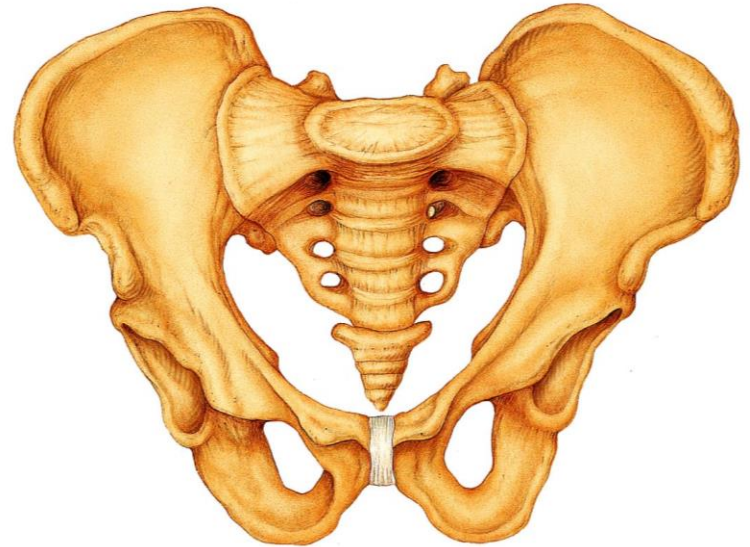
Acetabulum



- Where all three hip bones are fused.
- Receives the head of the femur (hip joint).

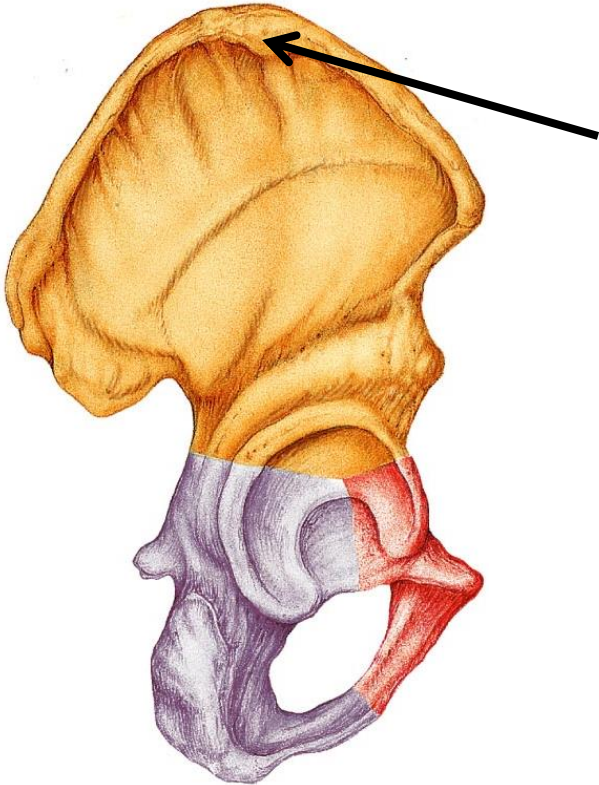
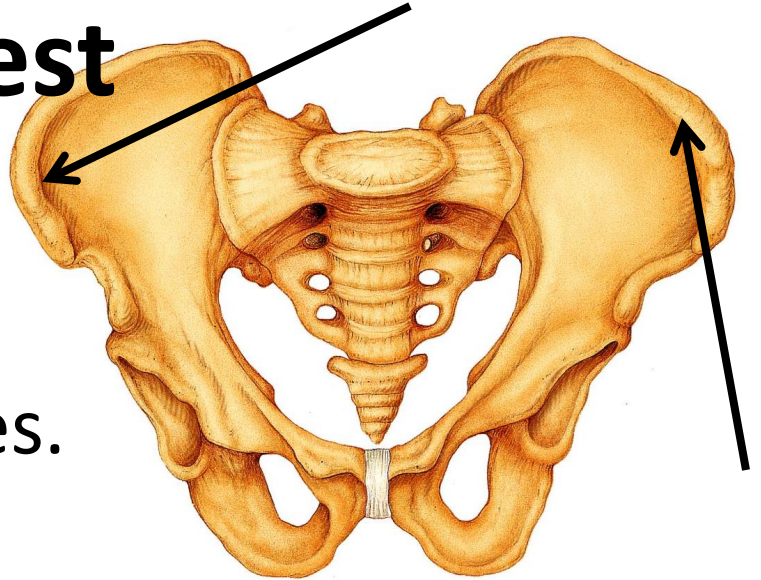
Ala

- Wing-like portion



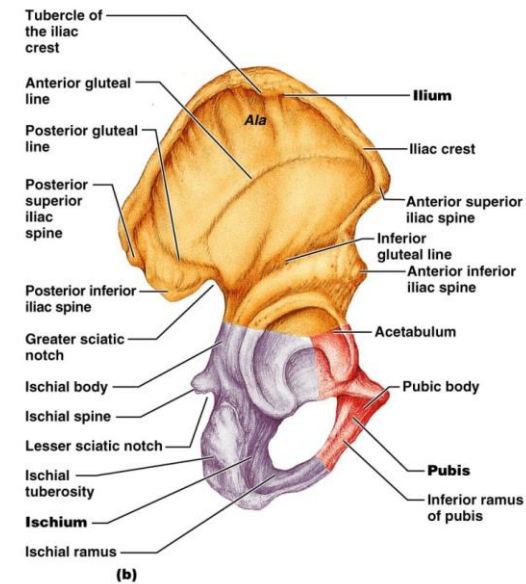
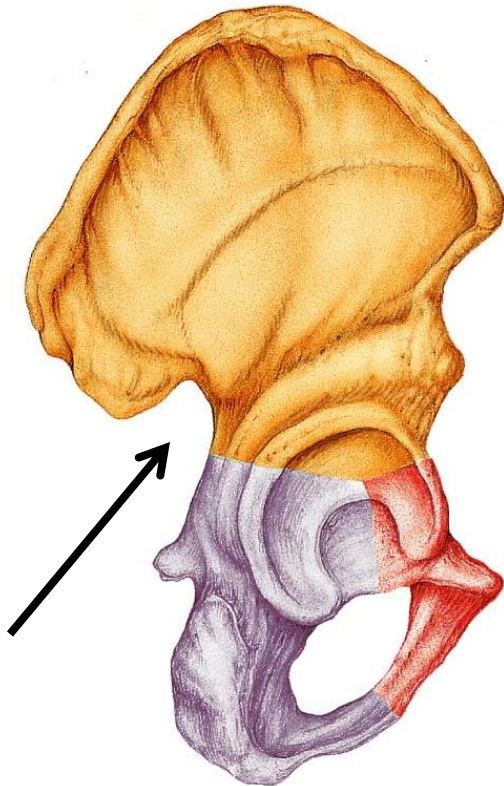
Iliac Crest

- Thickened superior margin.
- Where you rest your hands.
- Attachment sites for muscles.



Greater Sciatic Notch

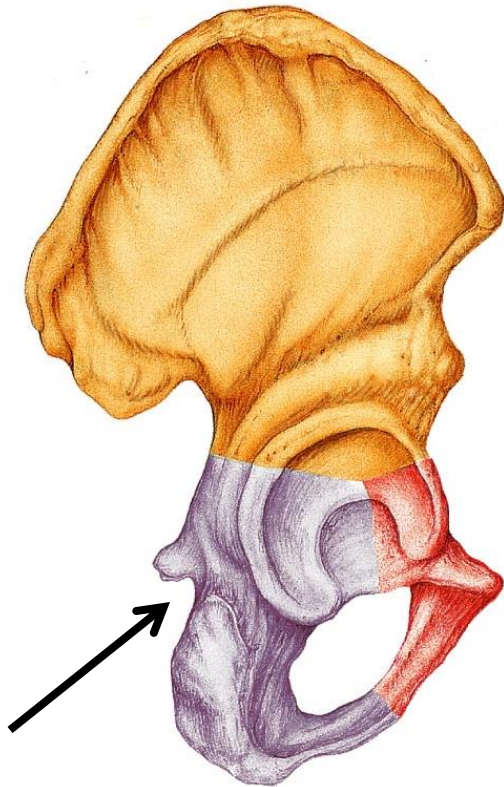
- Sciatic nerve passes to enter the thigh.
Longest nerve in the body.



Copyright © 2006 Pearson Education, Inc., publishing as Benjamin Cummings.

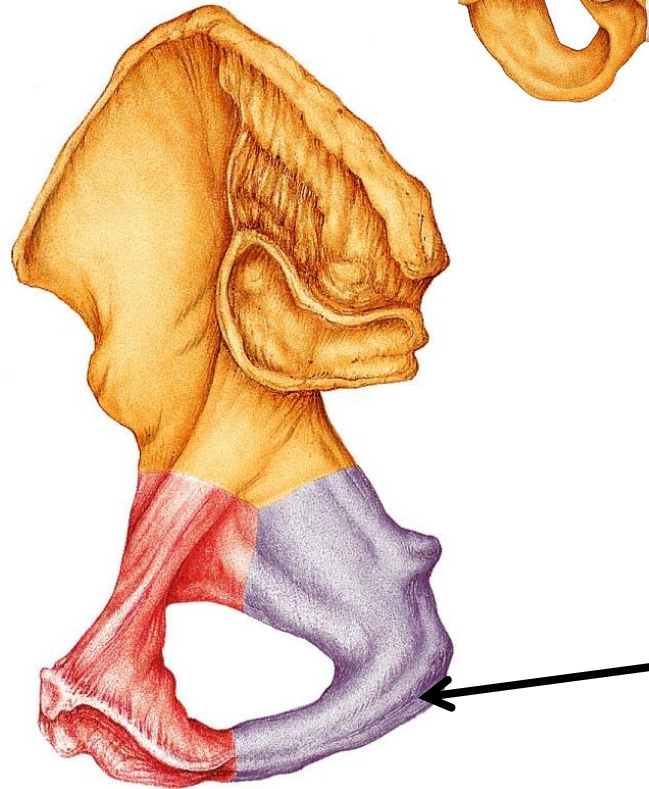
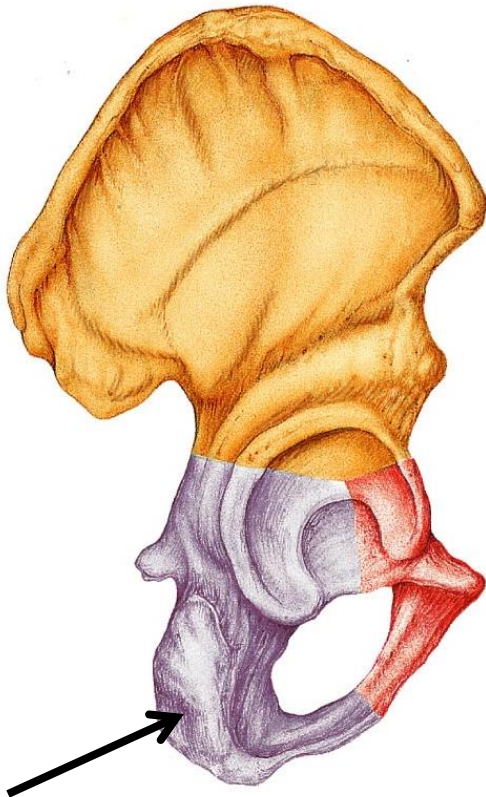
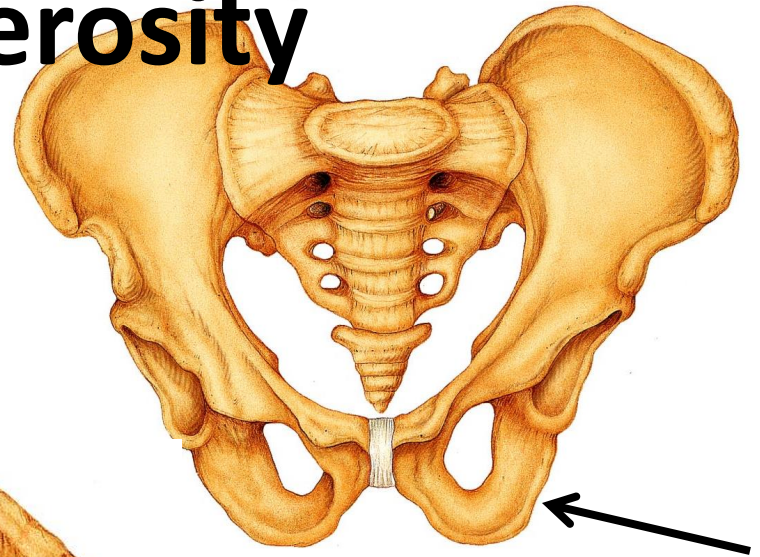
Lesser Sciatic Notch

- Nerves and blood vessels pass here to supply anogenital (anus/genital) region.



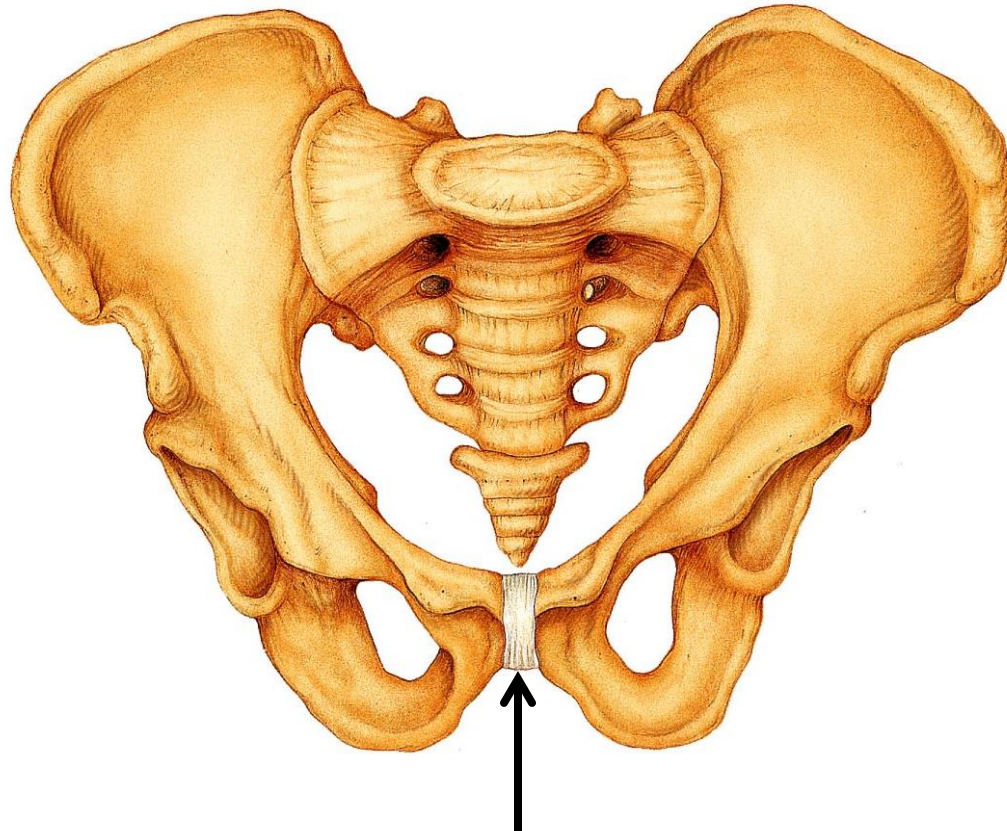
Ischial Tuberosity

- When we sit, all our weight is here!



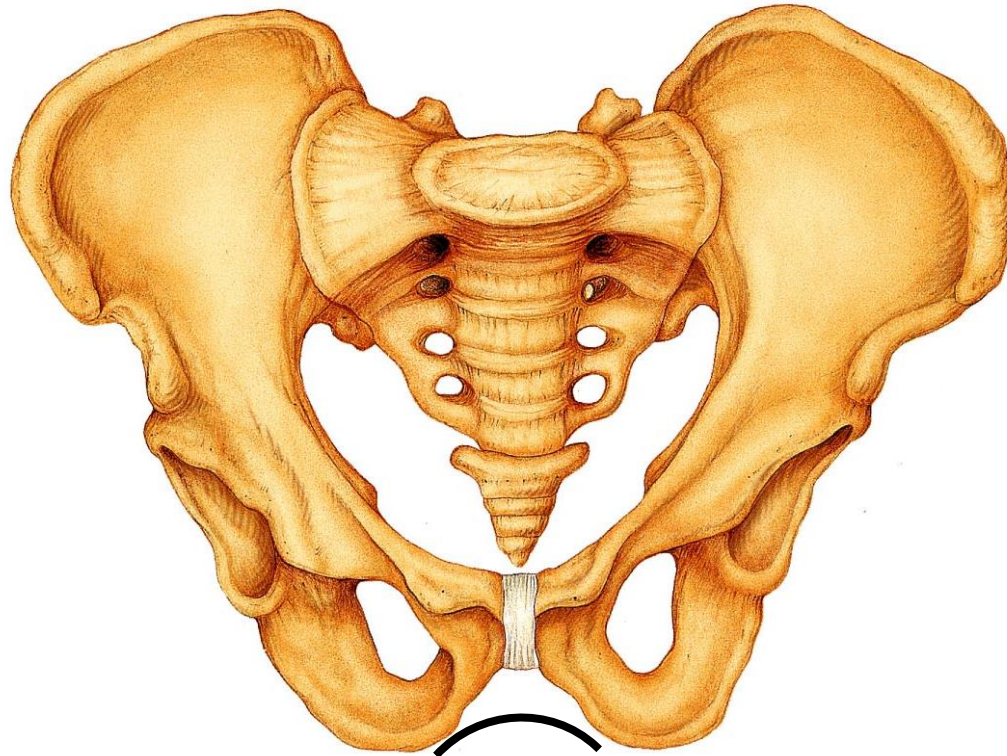
Pubic Symphysis

- The two bodies of the pubic bones are joined here by fibrocartilage



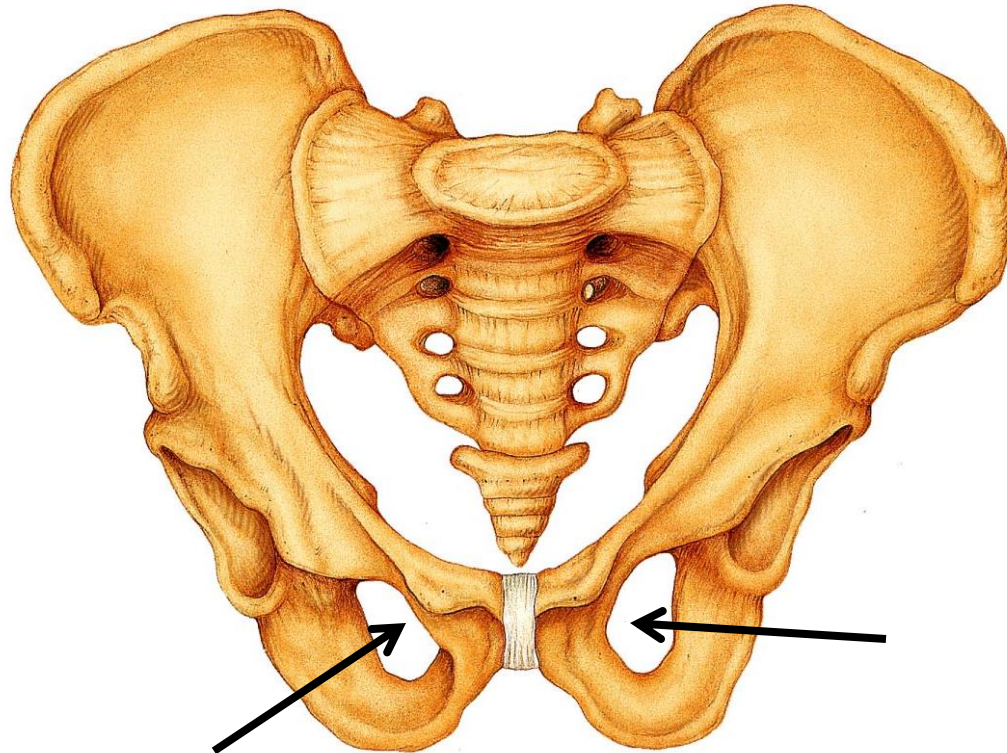
Pubic Arch

- The V-shaped angle formed when the pubic bones join



Obturator Foramen

- Large opening in the hip bone
- Where the pubis and ischium join.
- Few blood vessels and nerves pass.



- Differences between male and female pelvis
→ see handout!