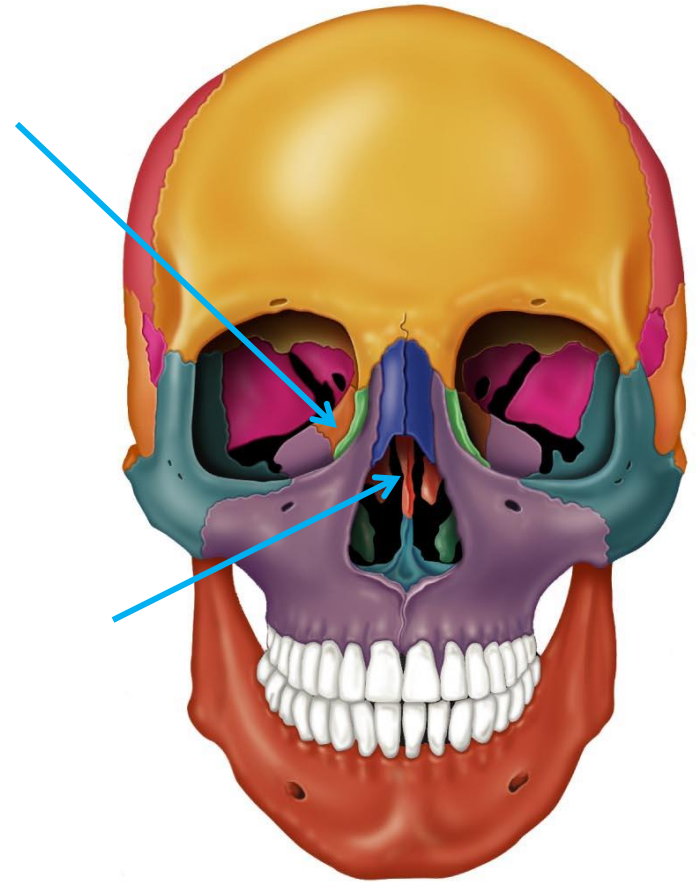
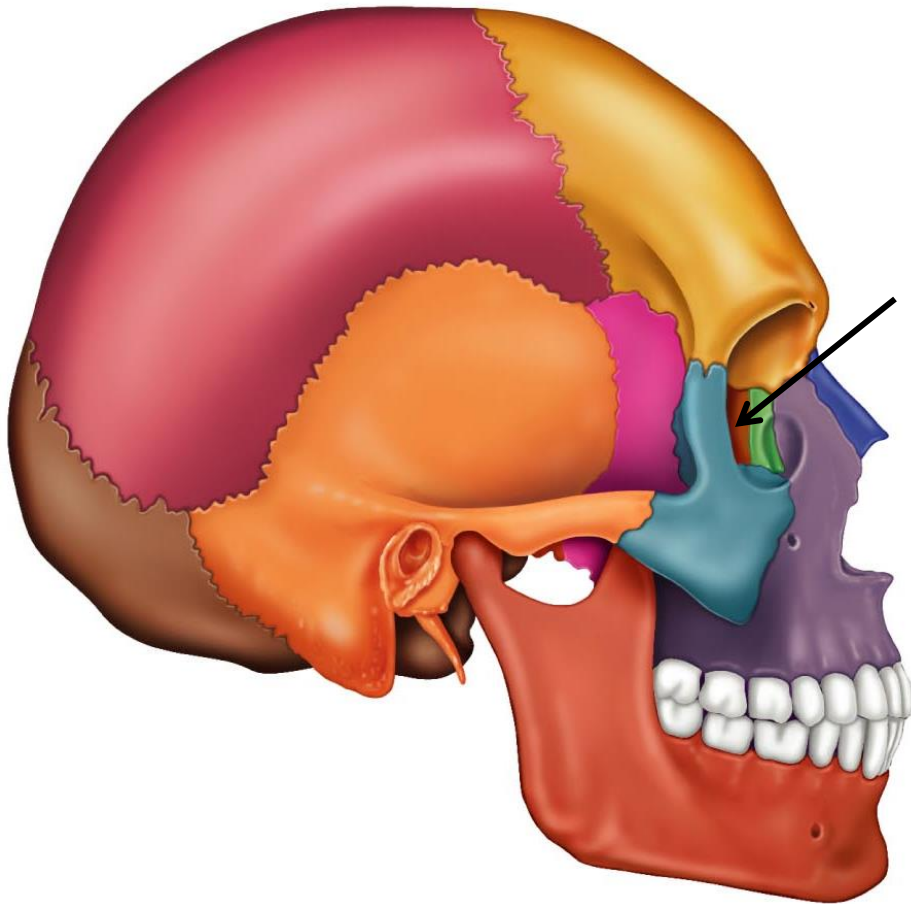


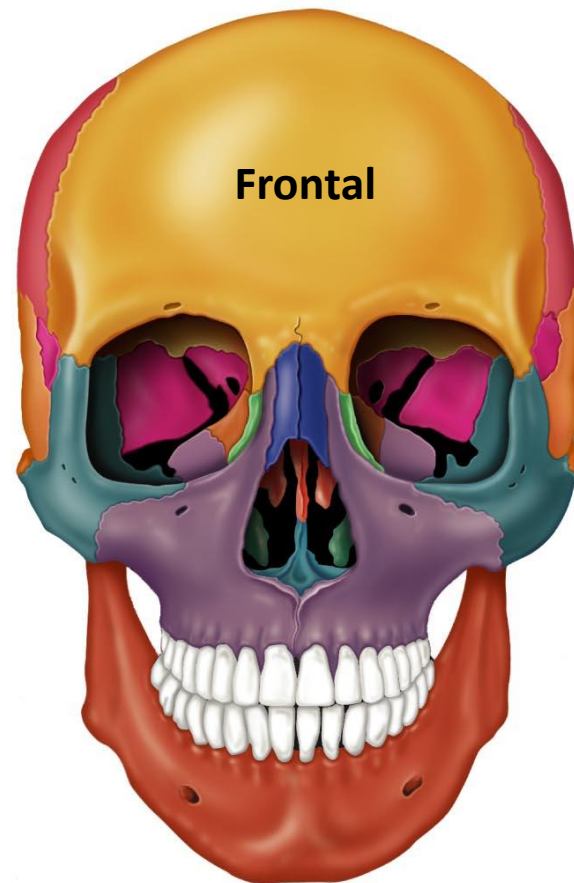
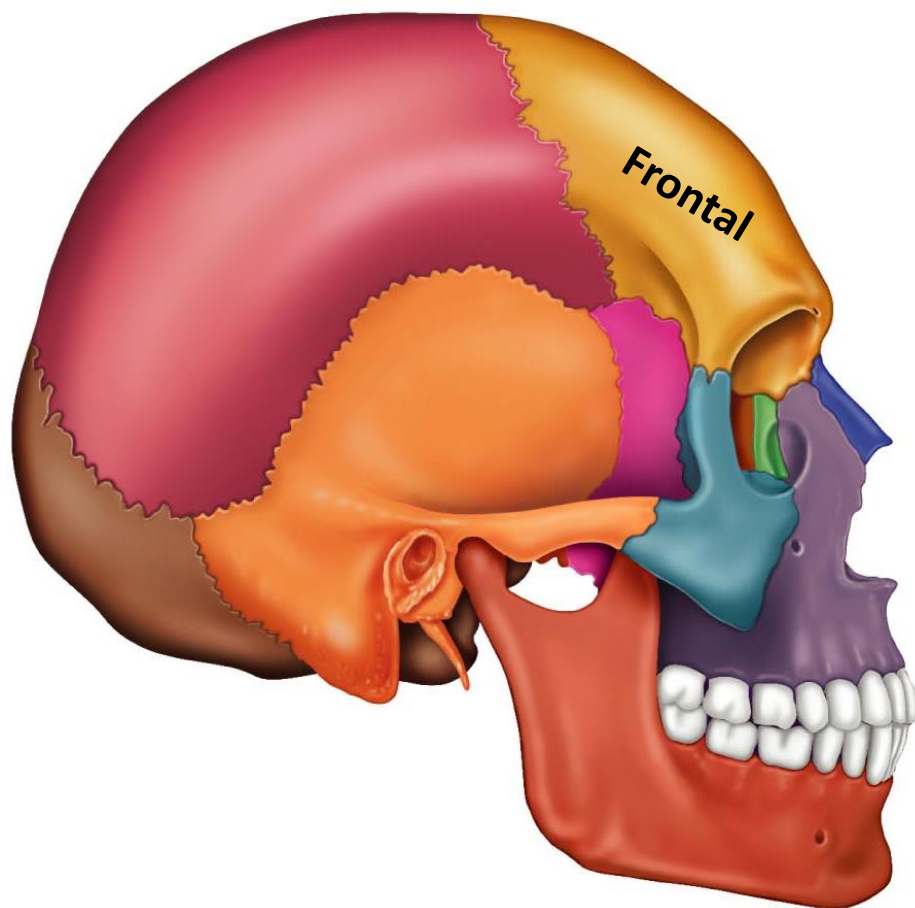
# **Axial Skeleton**

## **Skull and Facial Bones**

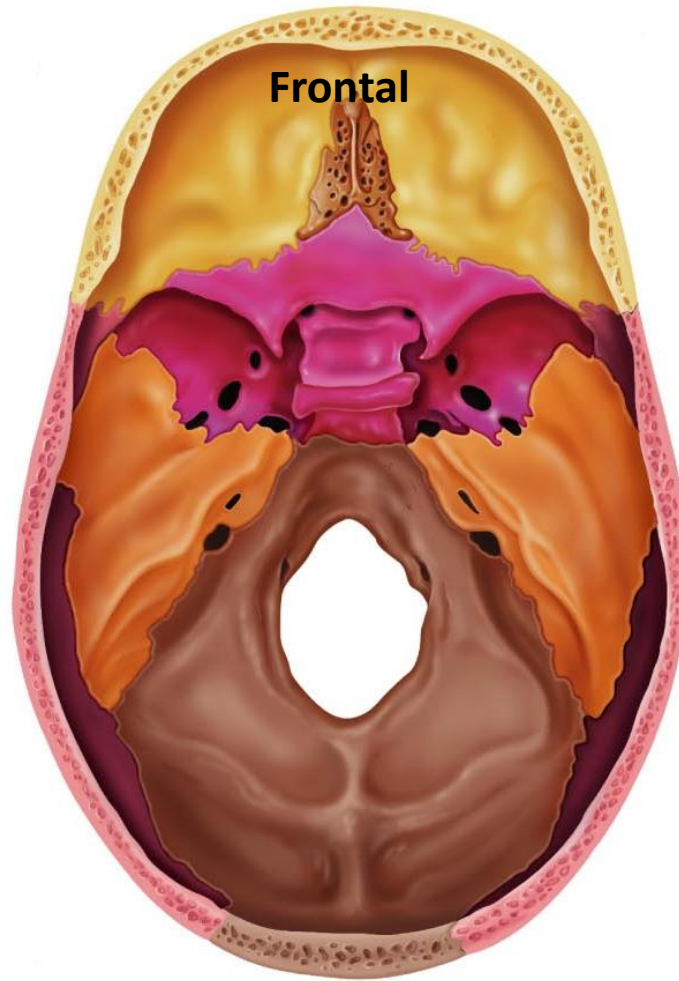
# Ethmoid



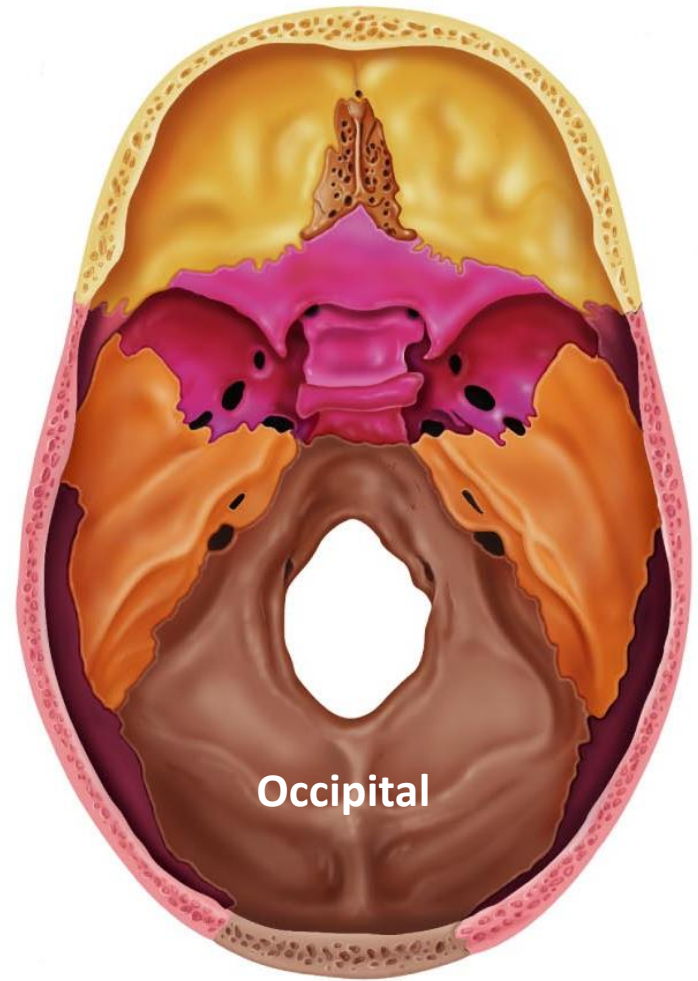
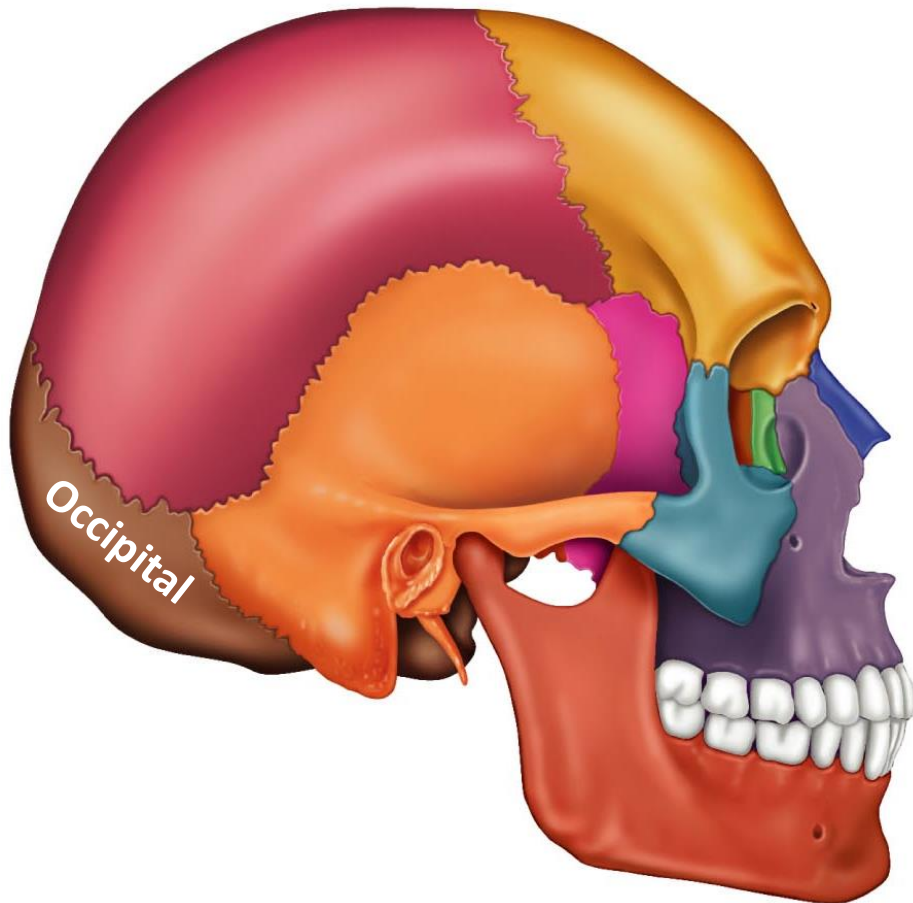
# Frontal



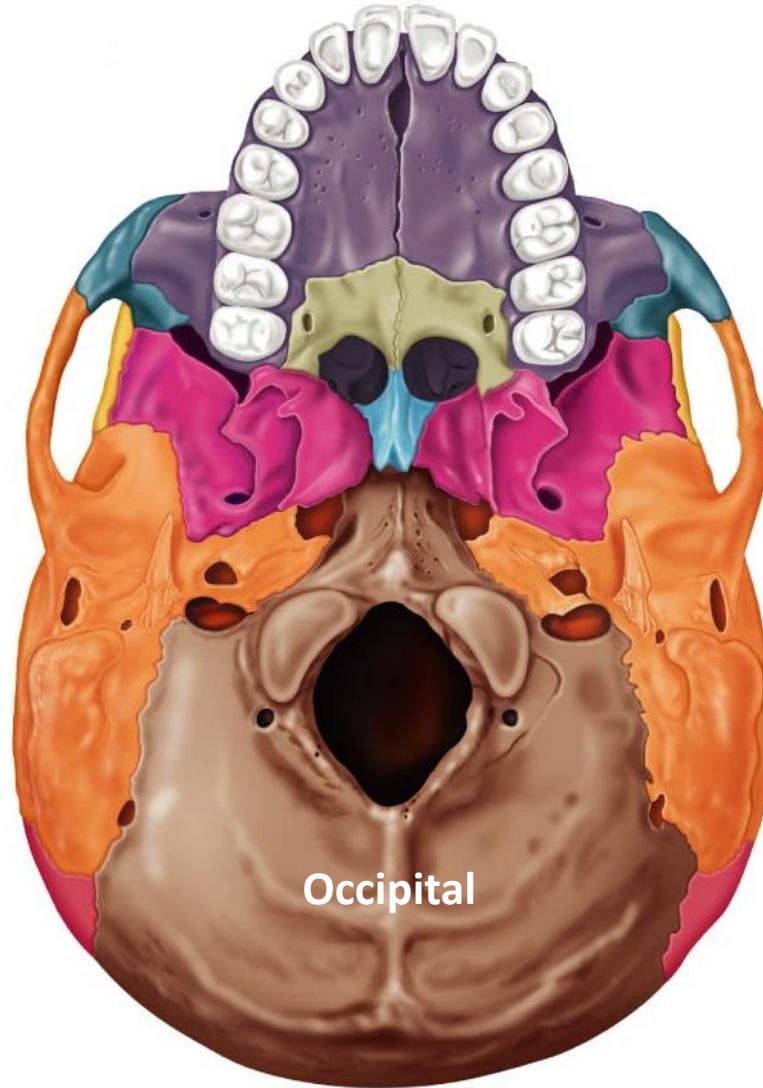
# Frontal



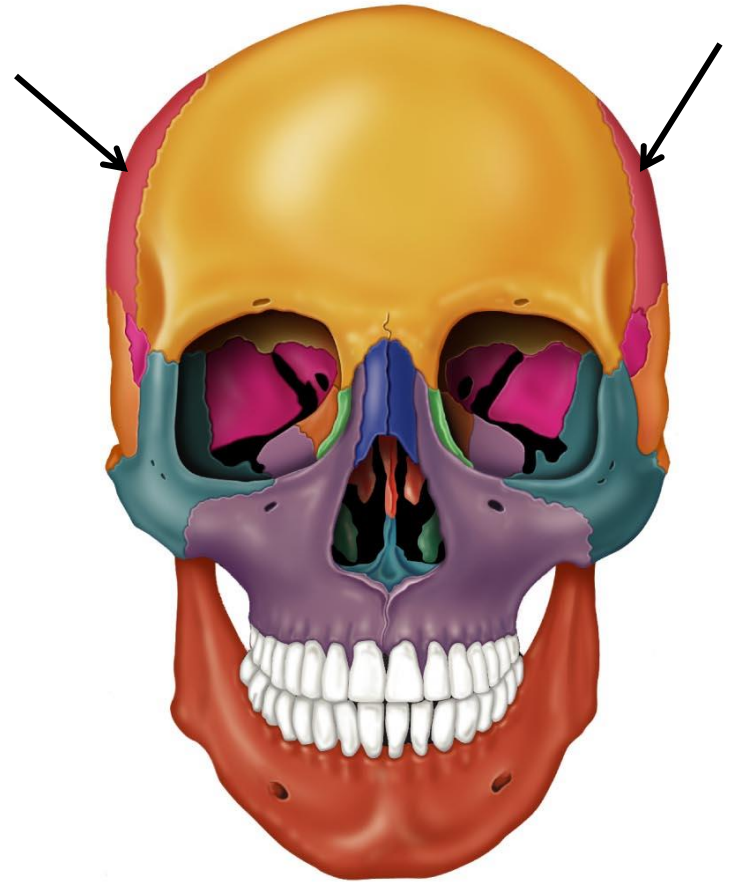
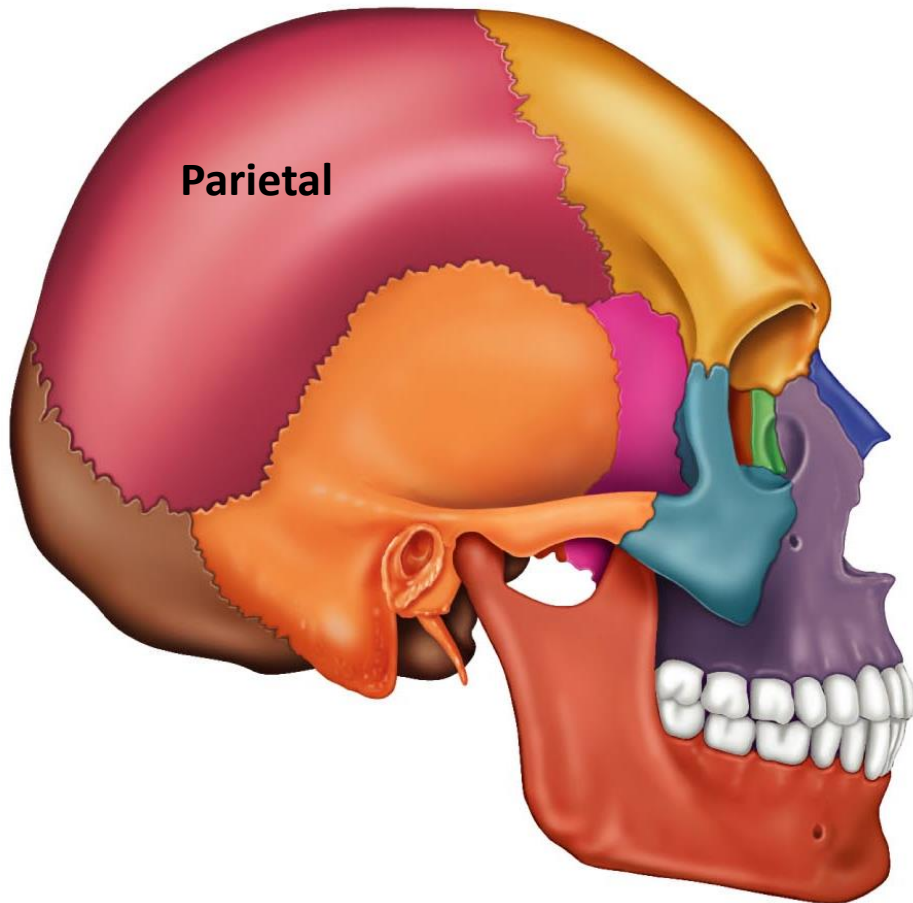
# Occipital



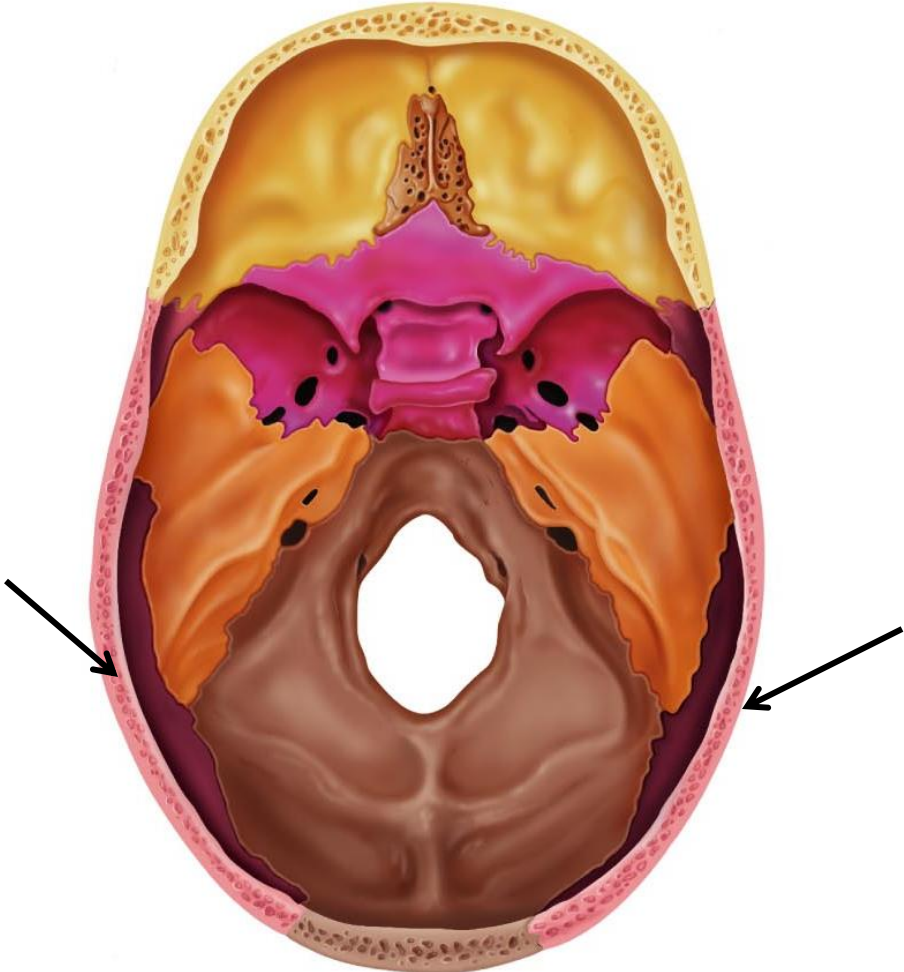
# Occipital



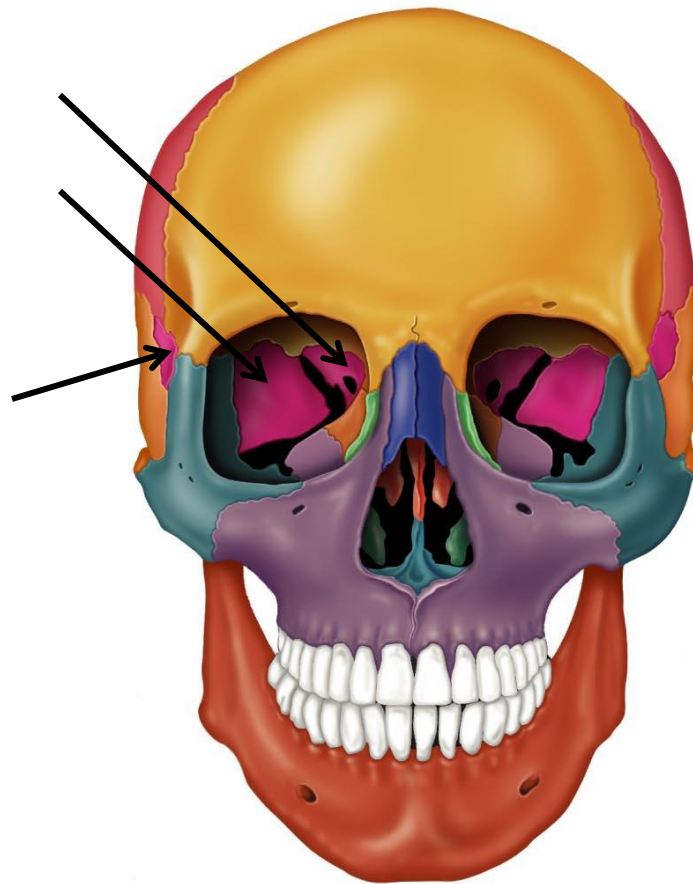
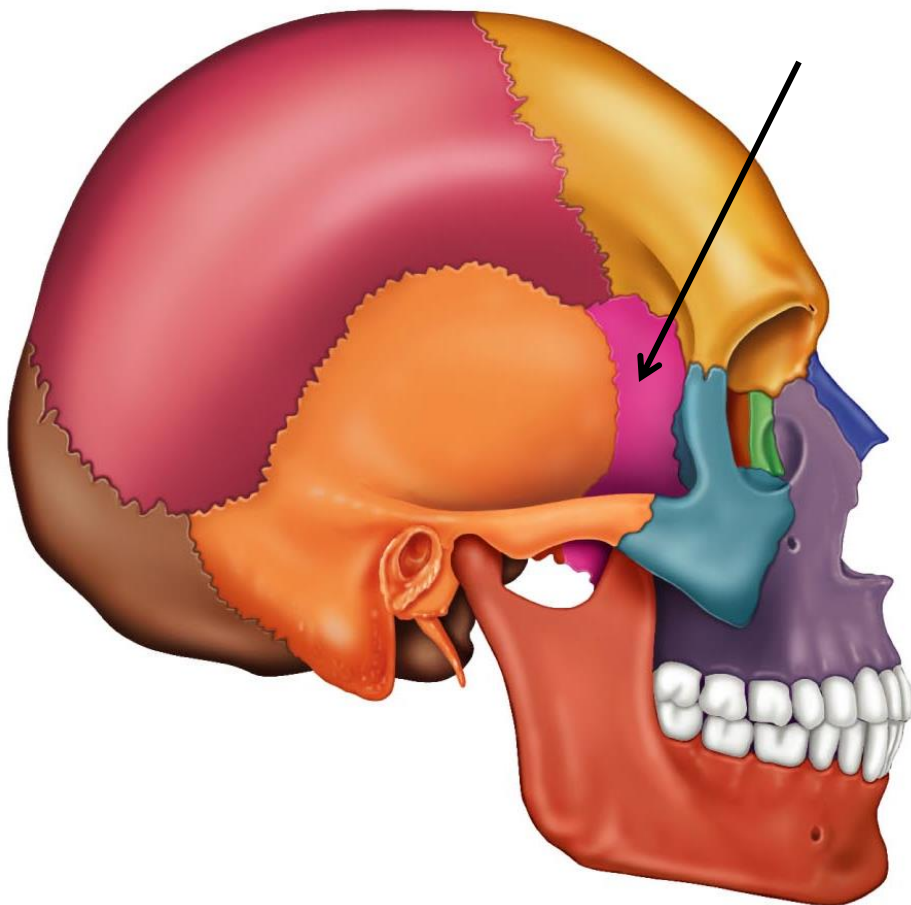
# Parietal



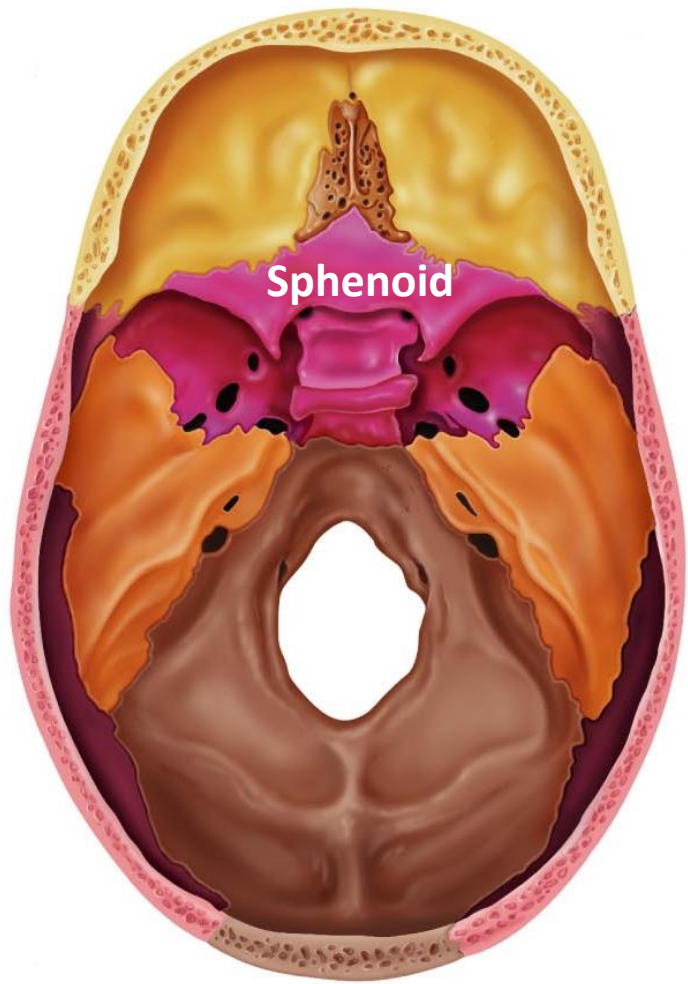
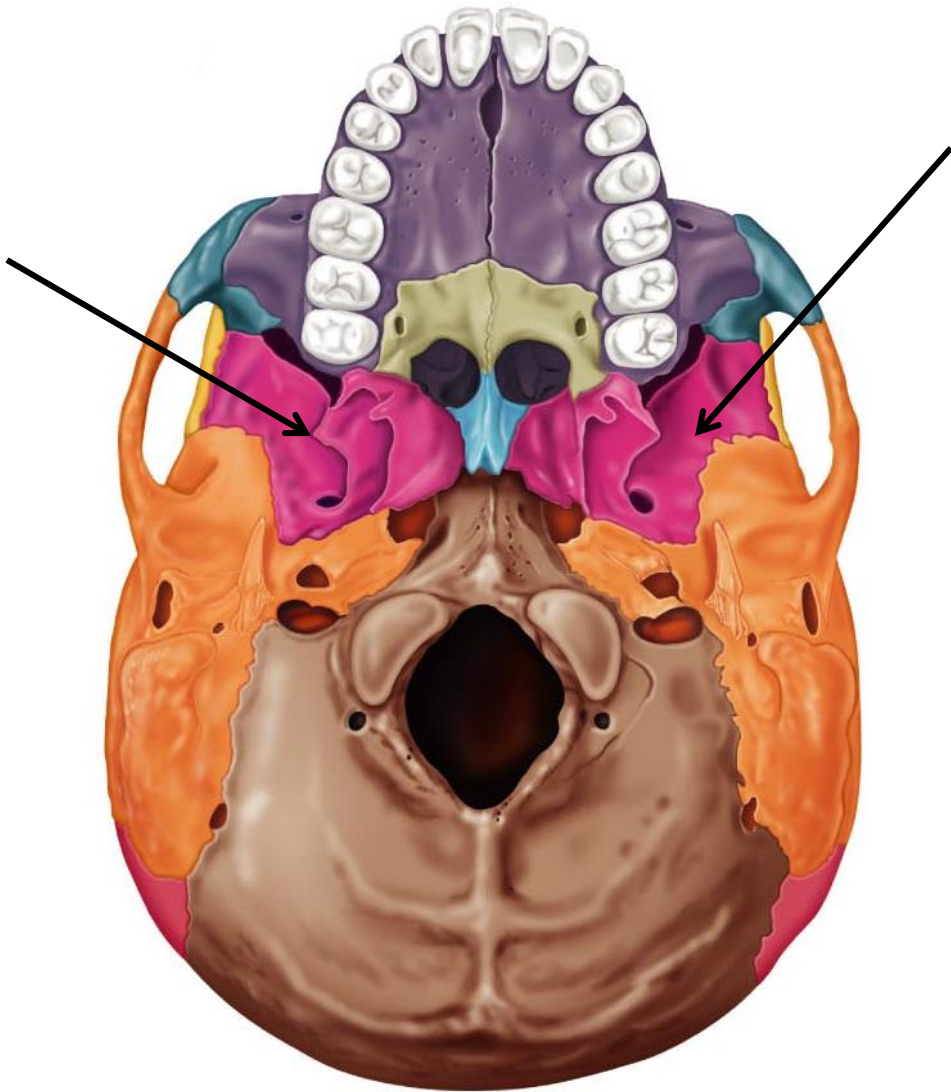
# Parietal



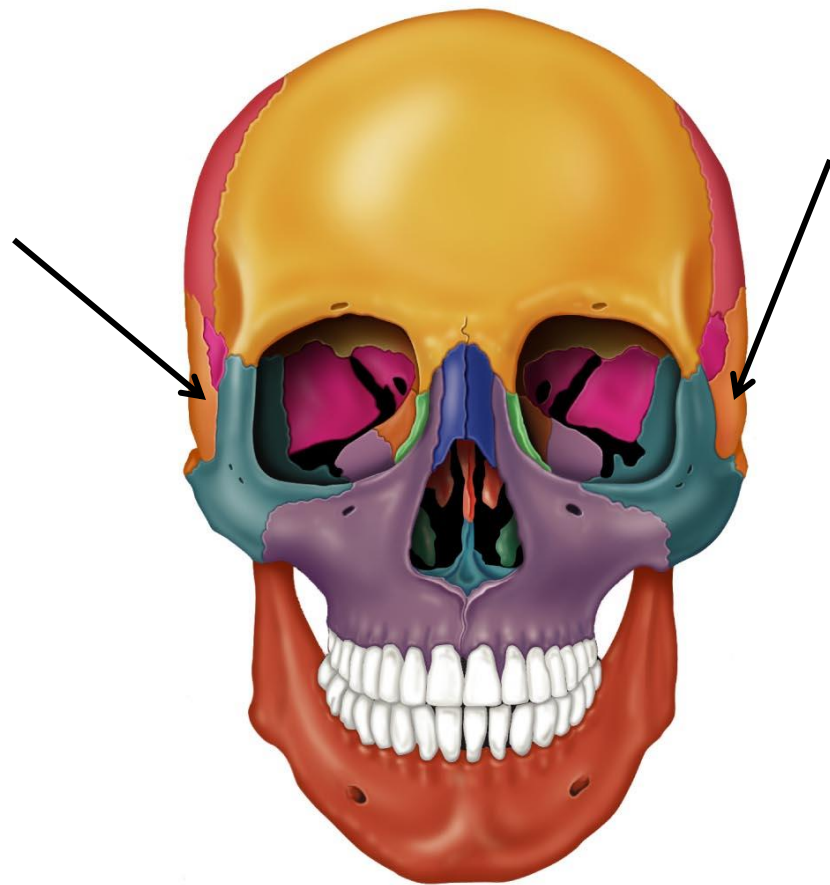
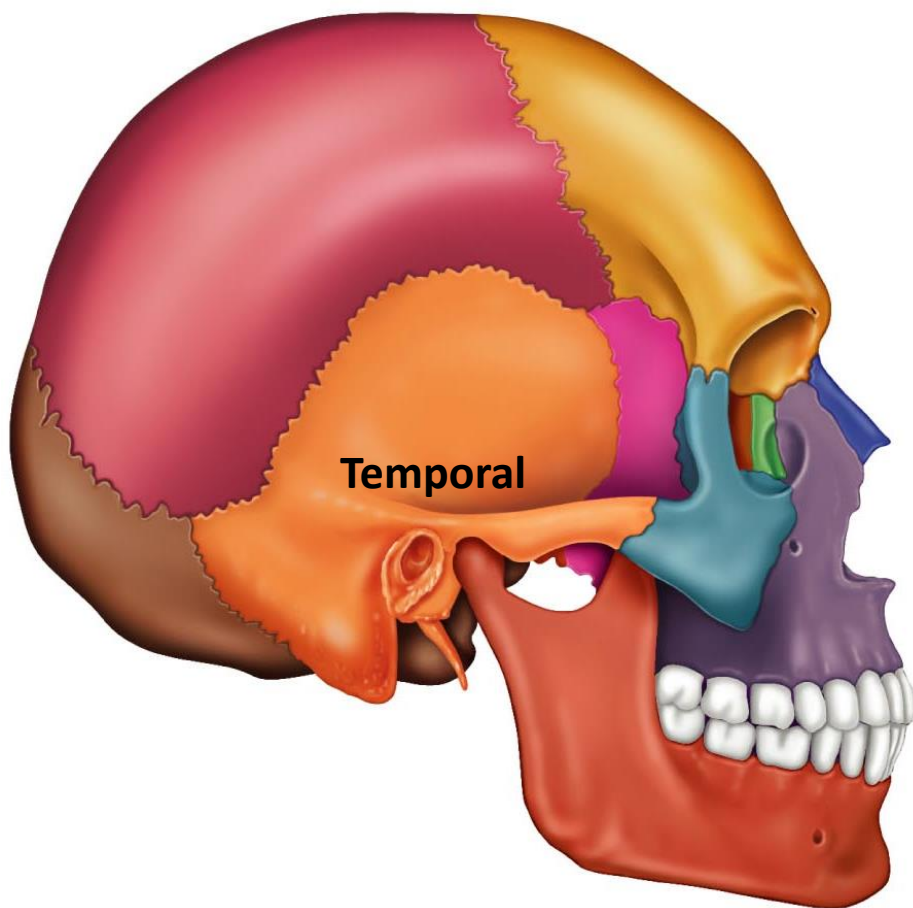
# Sphenoid



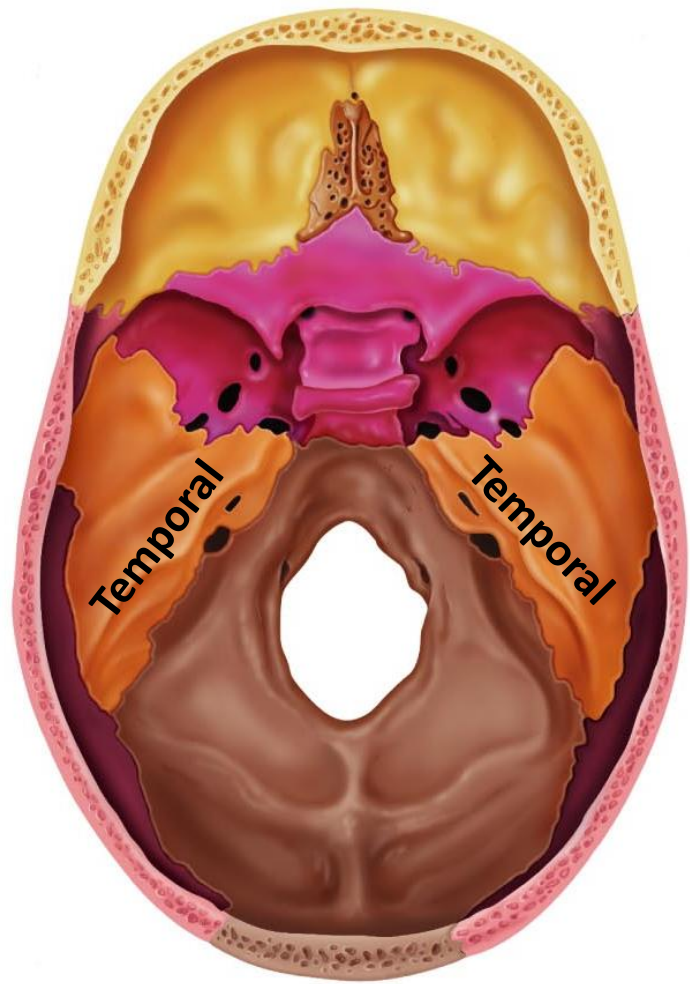
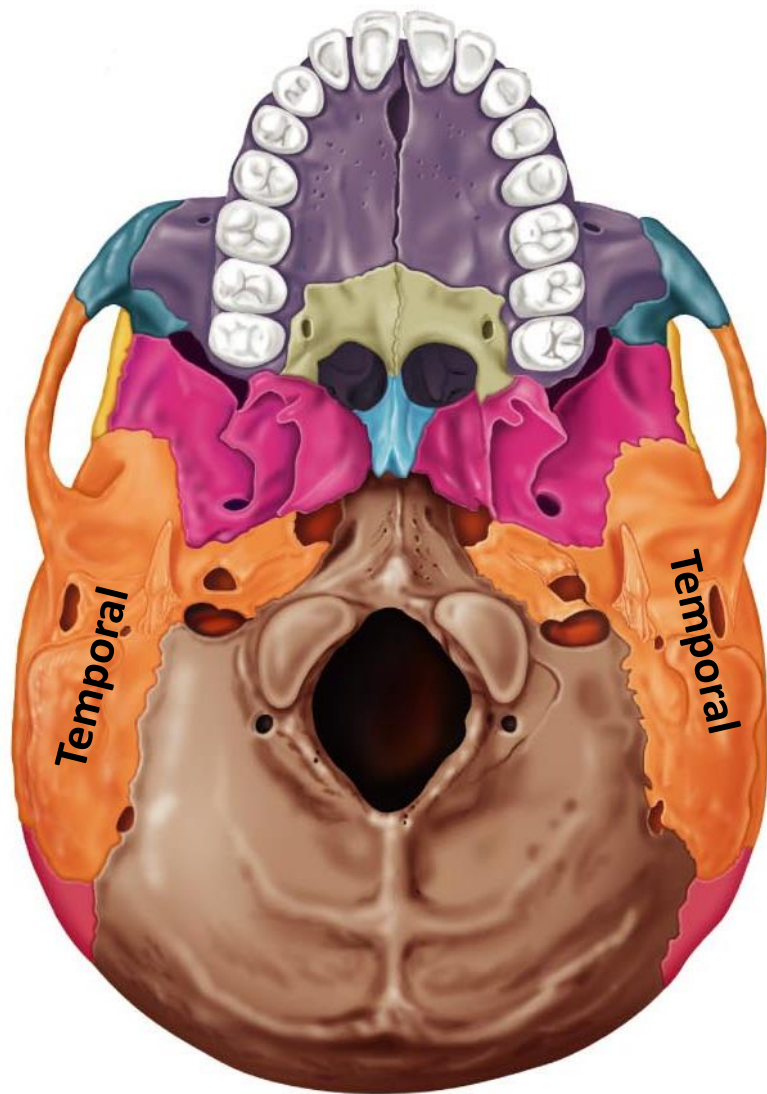
# Sphenoid



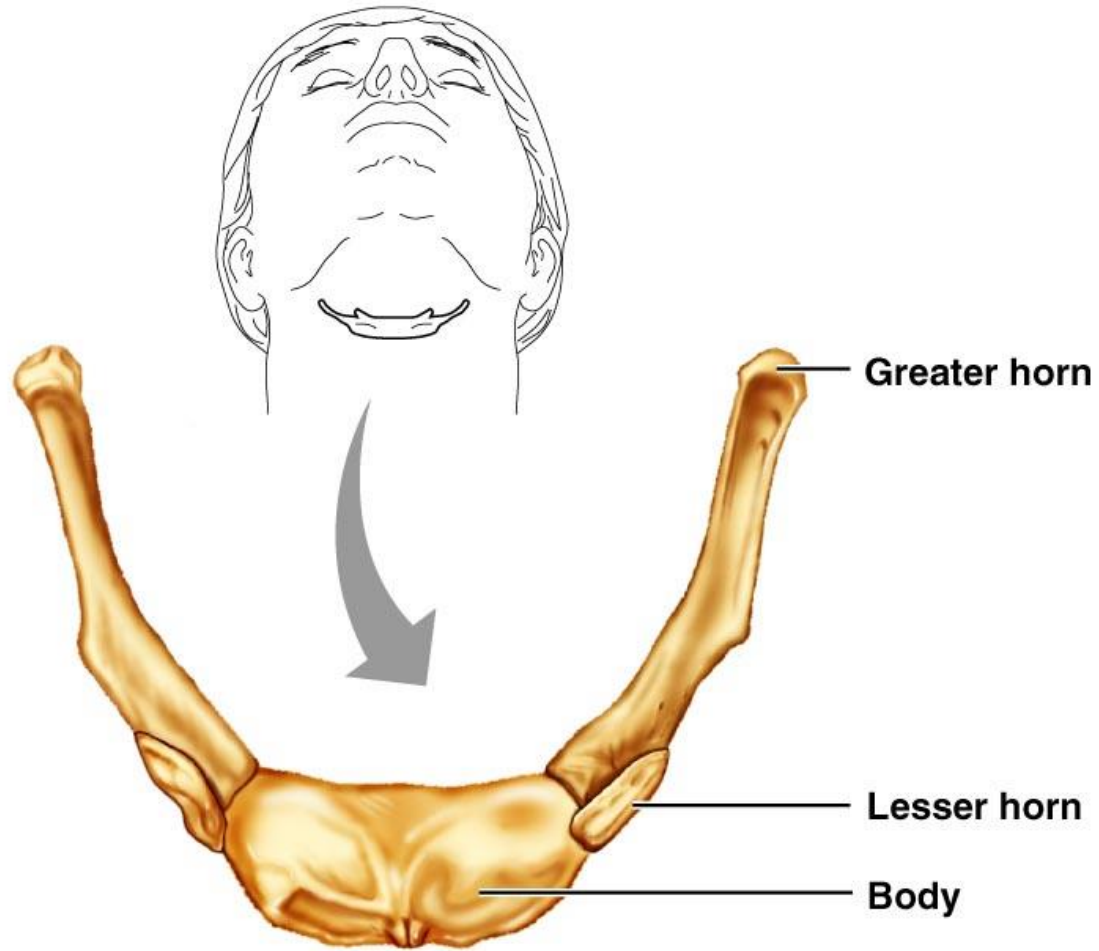
# Temporal



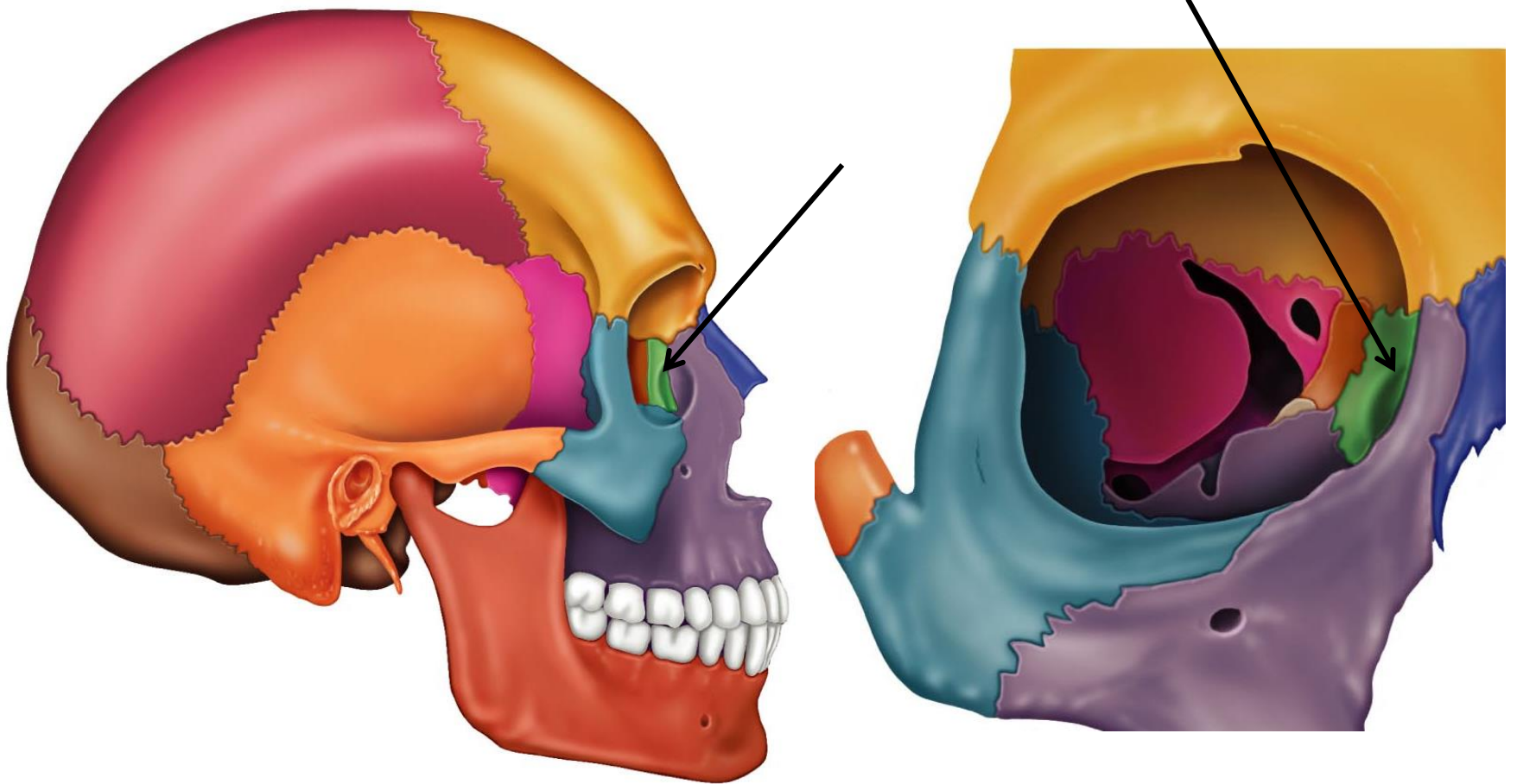
# Temporal



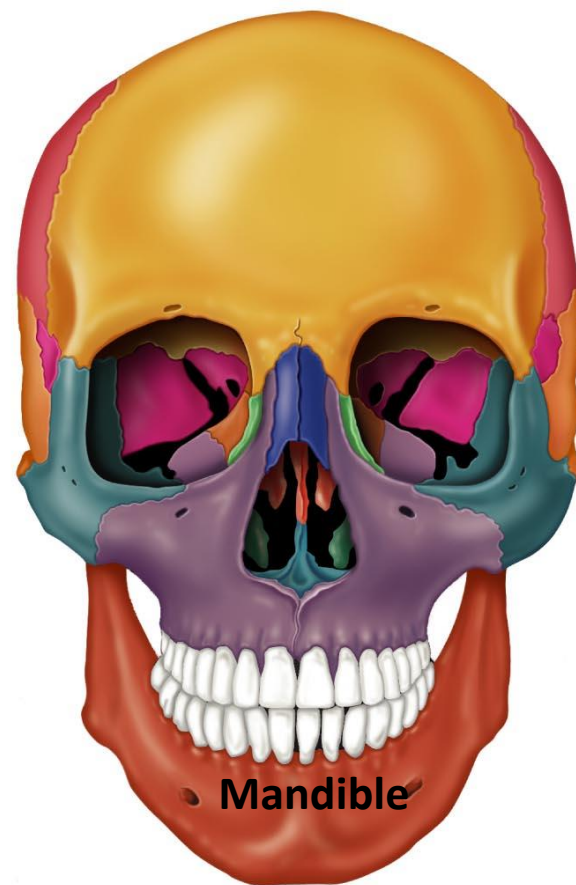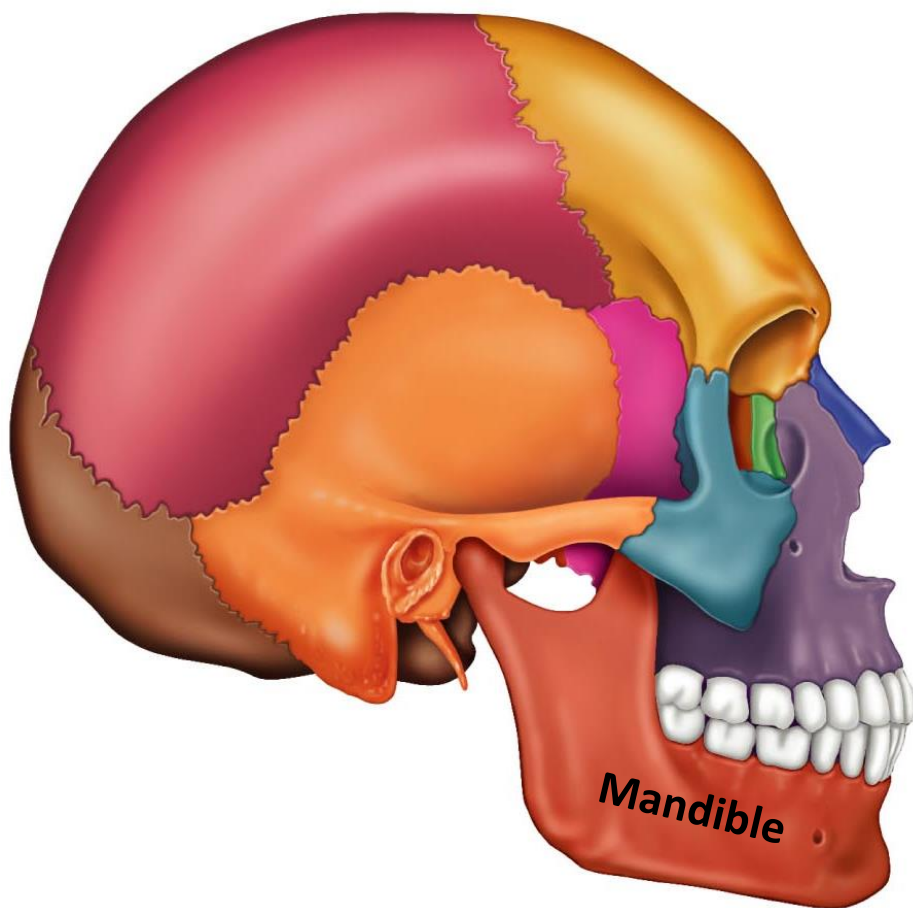
# Hyoid



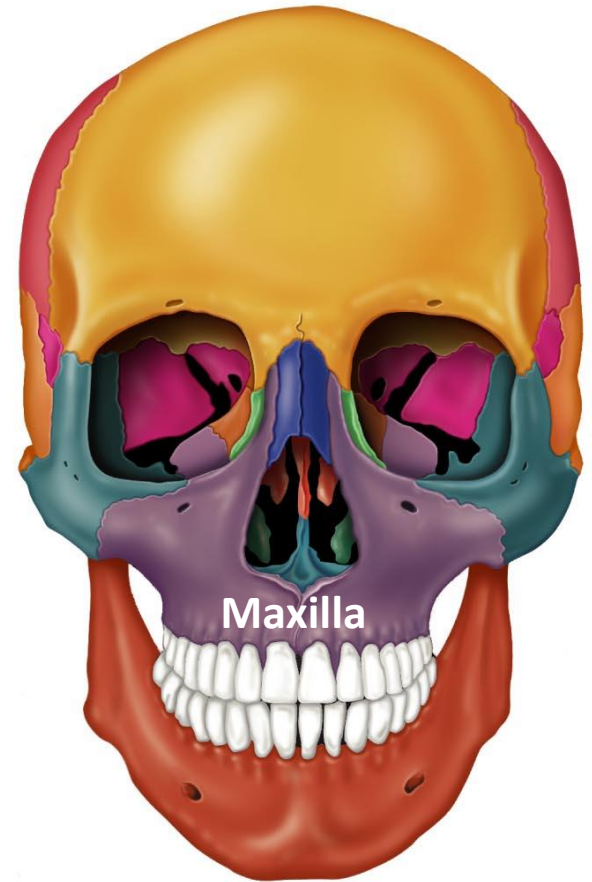
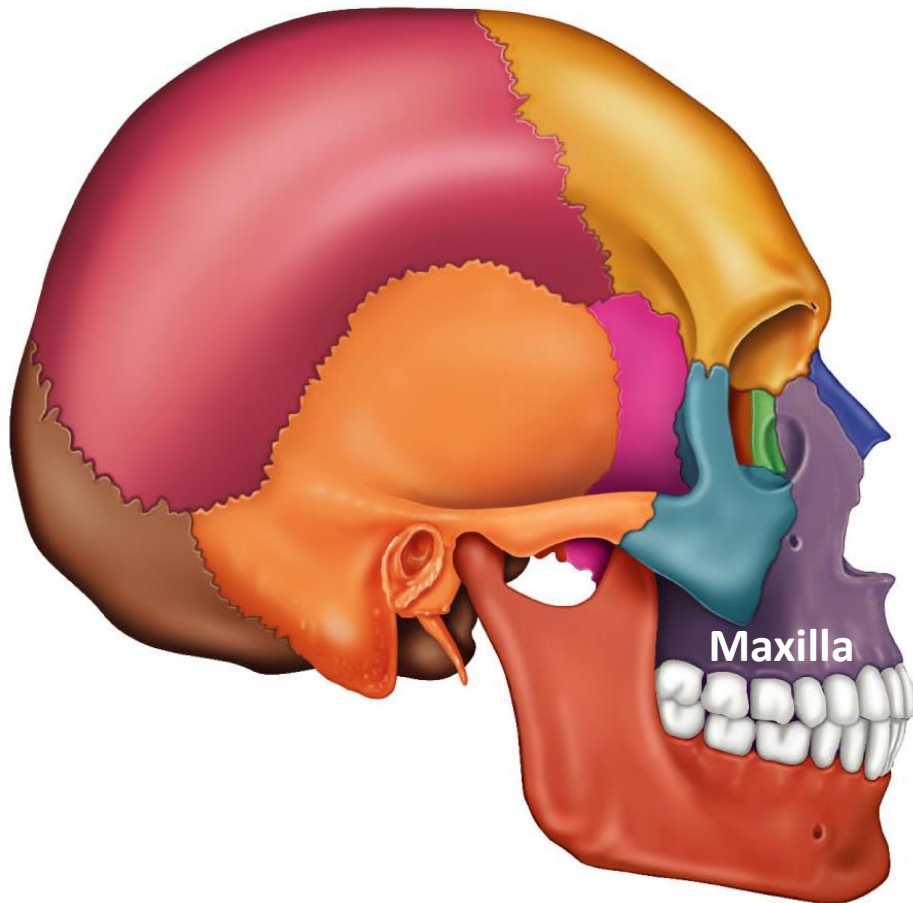
# Lacrimal



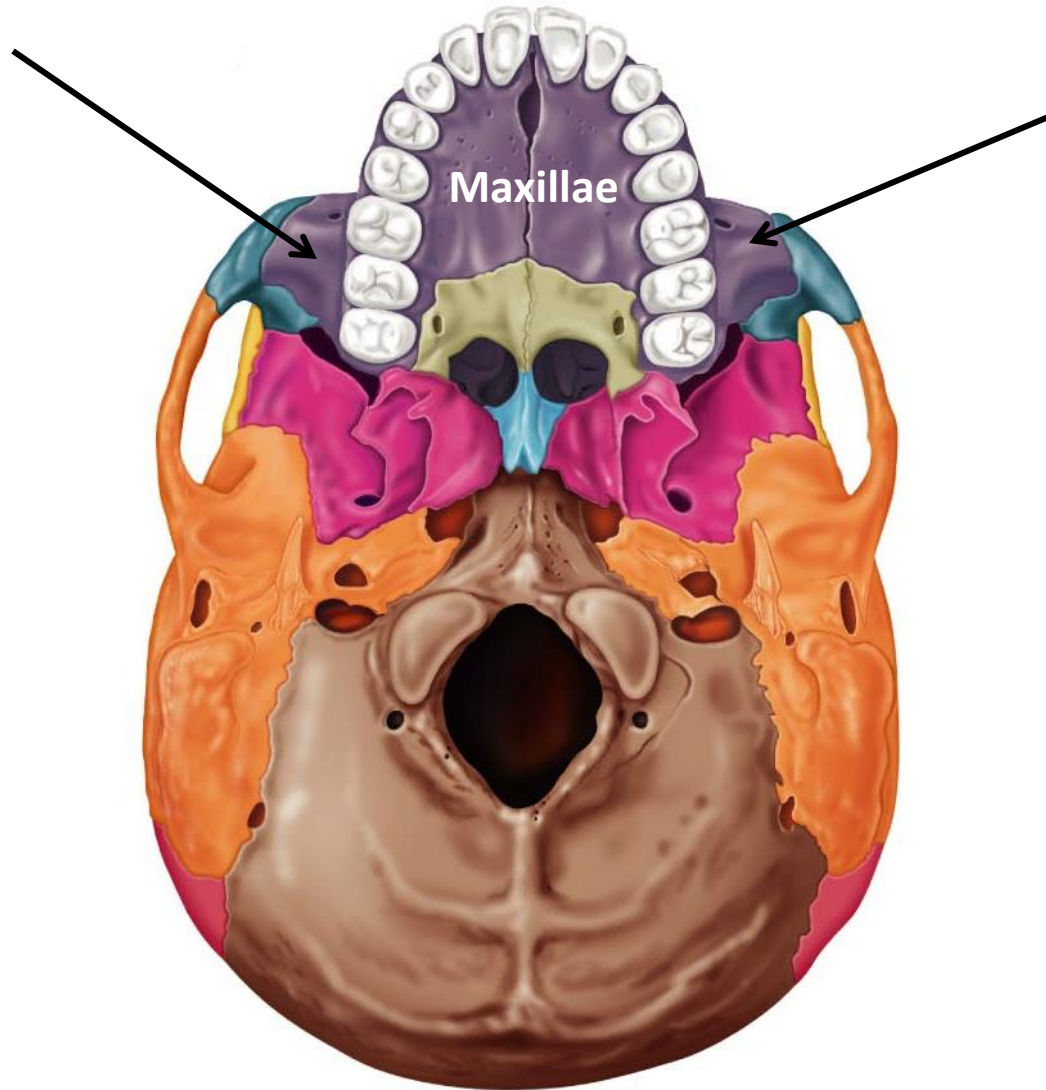
# Mandible



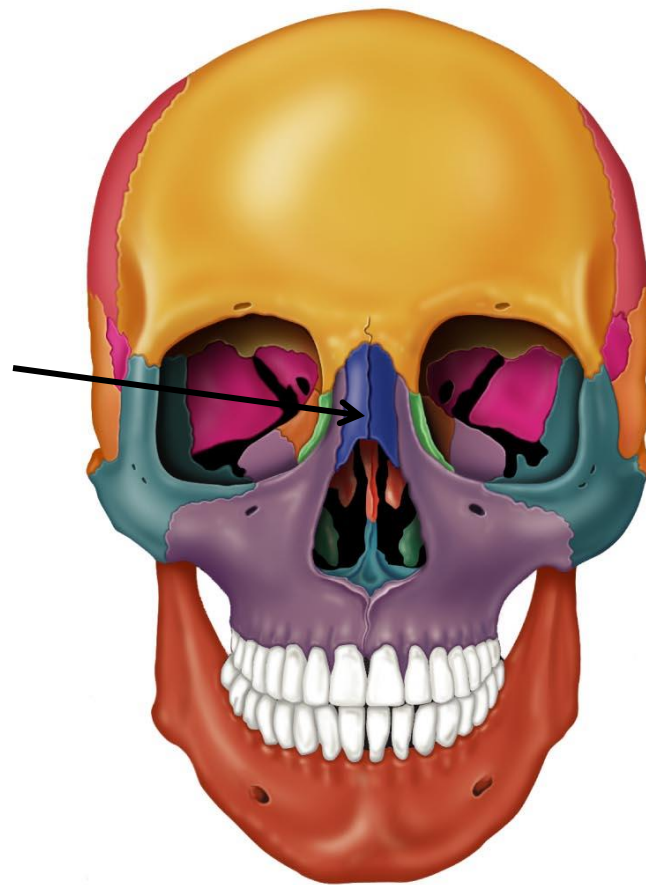
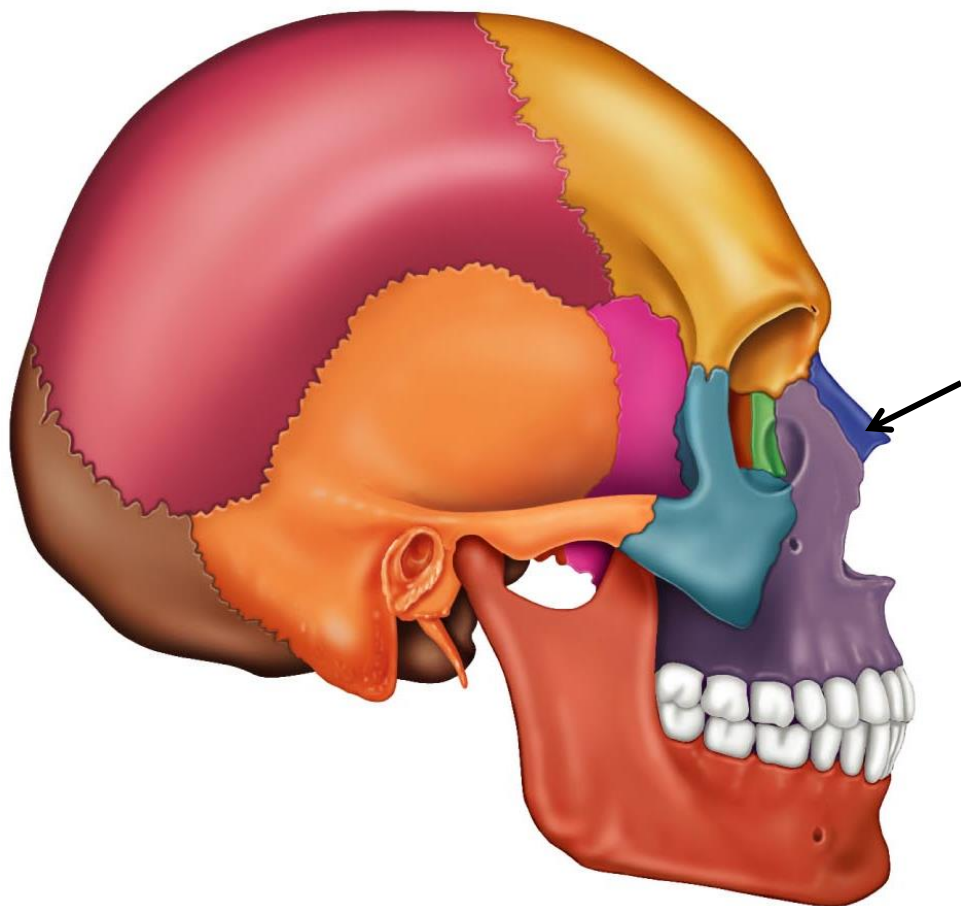
# Maxilla



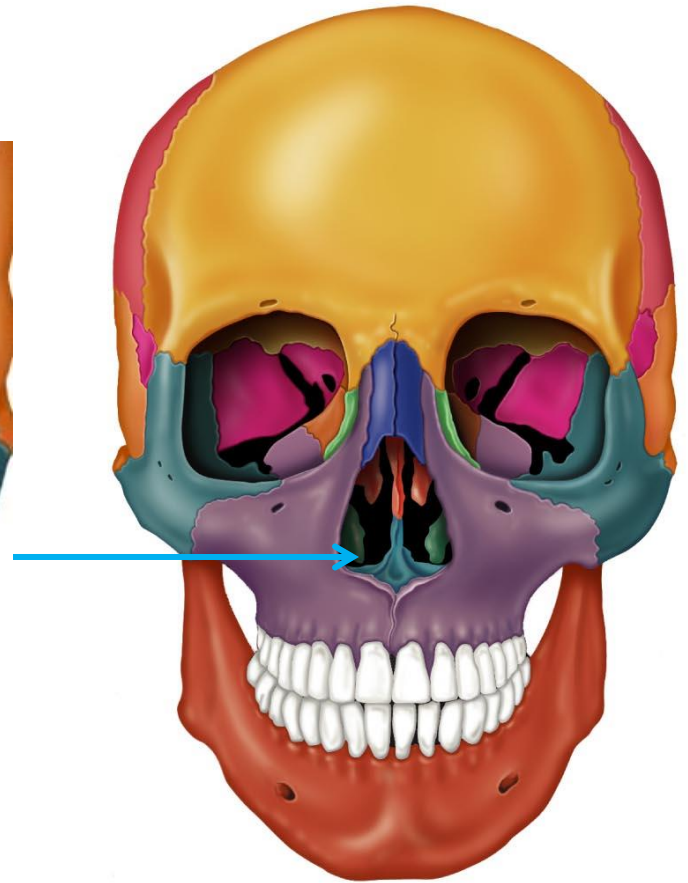
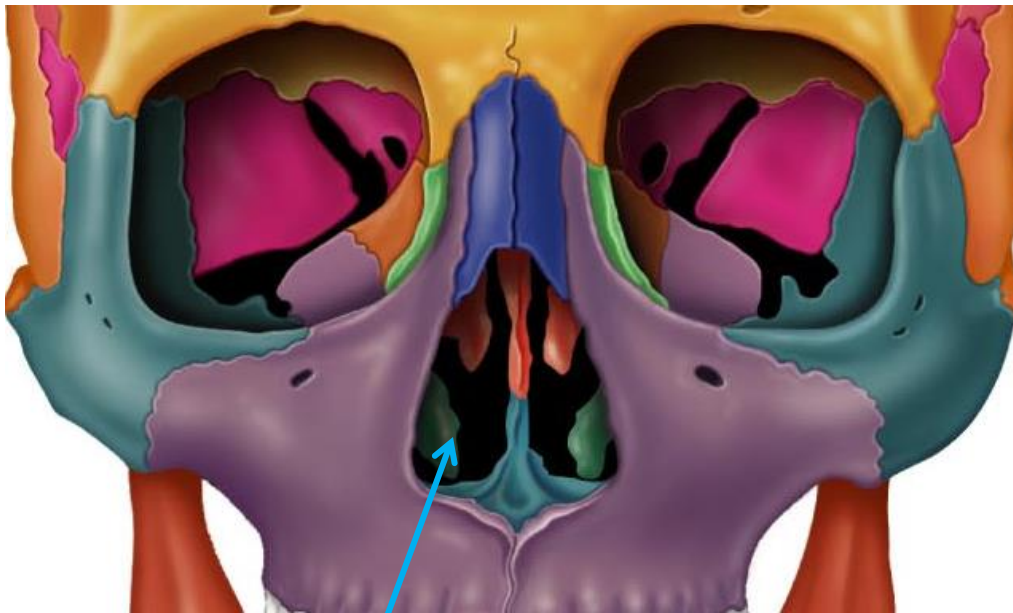
# Maxillae



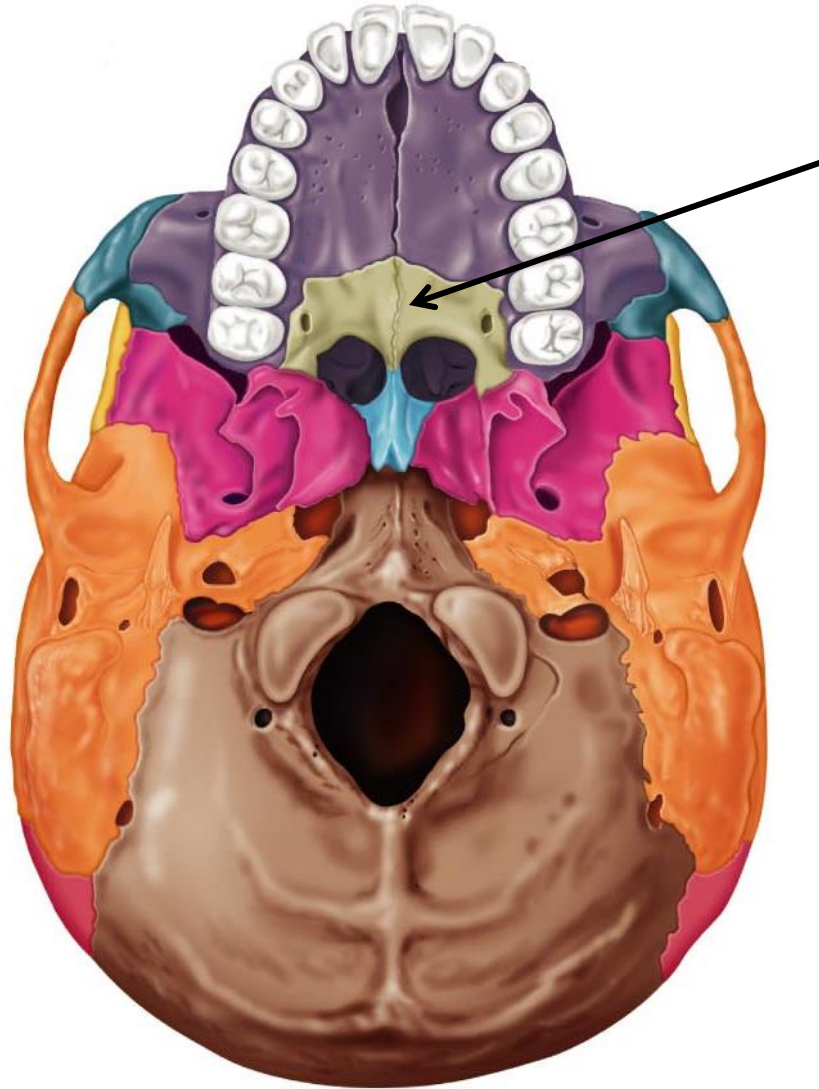
# Nasal



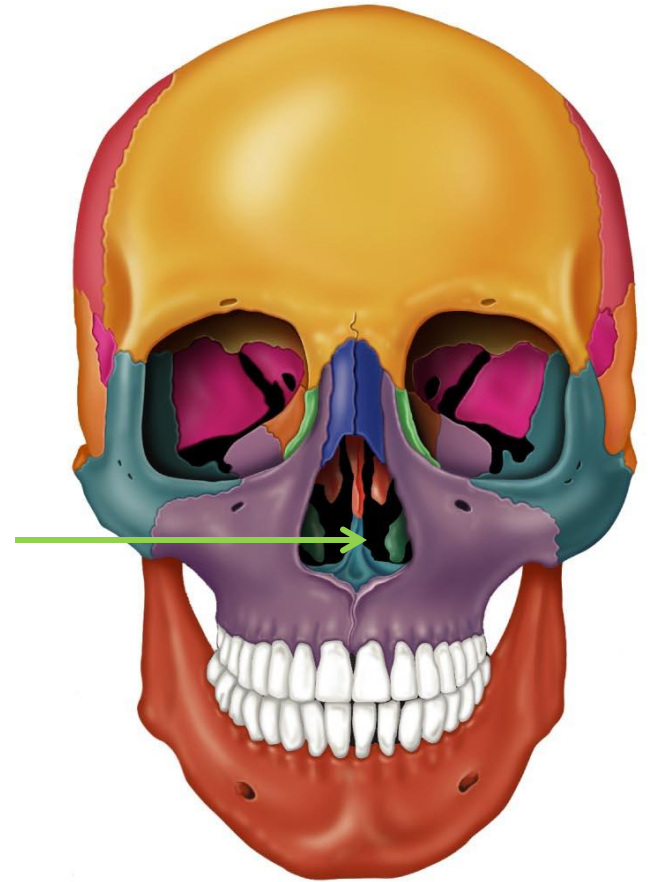
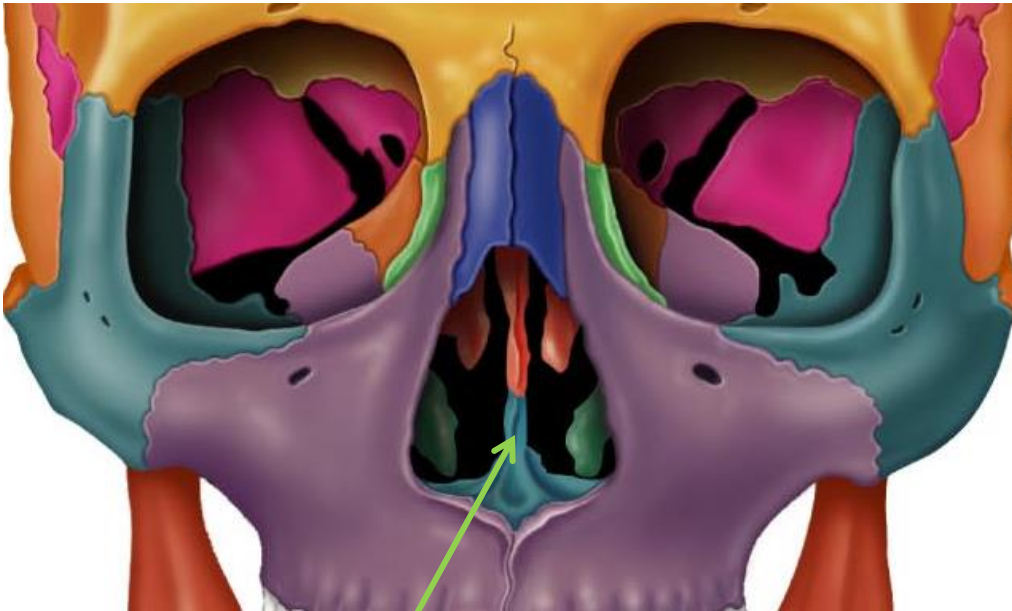
# Nasal Chonchae



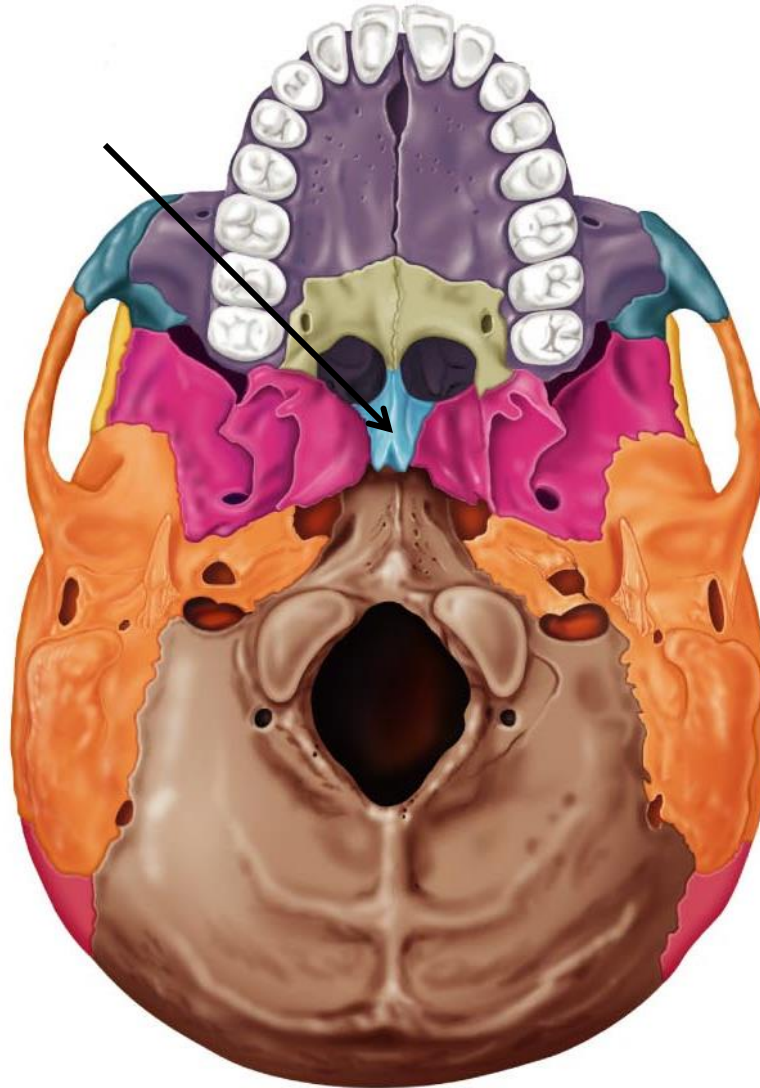
# Palatine



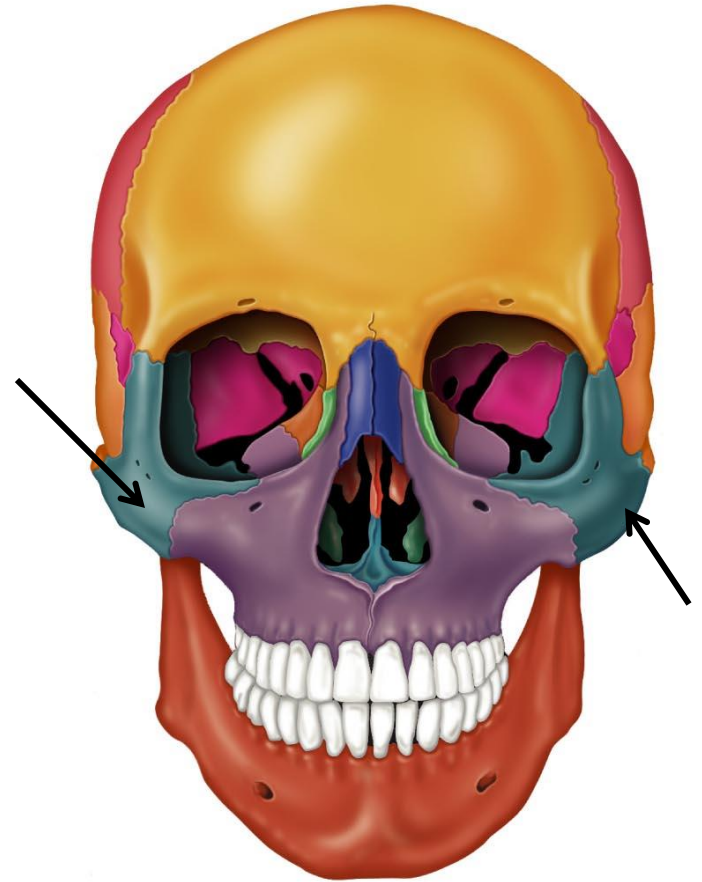
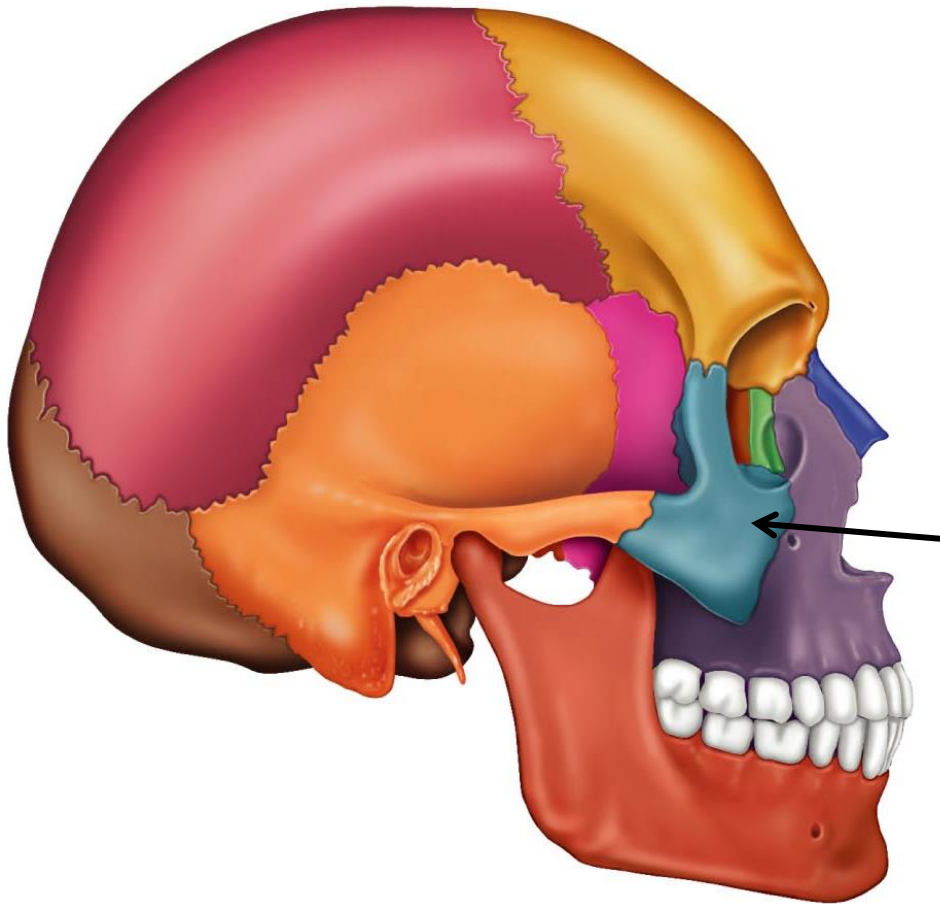
# Vomer



# Vomer



# Zygomatic



# Zygomatic

