

Nails

- Protective coverings at the ends of fingers and toes
- Plates of tightly packed, hard, keratinized epidermal cells
- Scale-like modification of epidermis
- Contains hard keratin
- Function
 - Protection against trauma to the ends of the digits
 - Help to grasp and manipulate small objects
 - Allow us to scratch

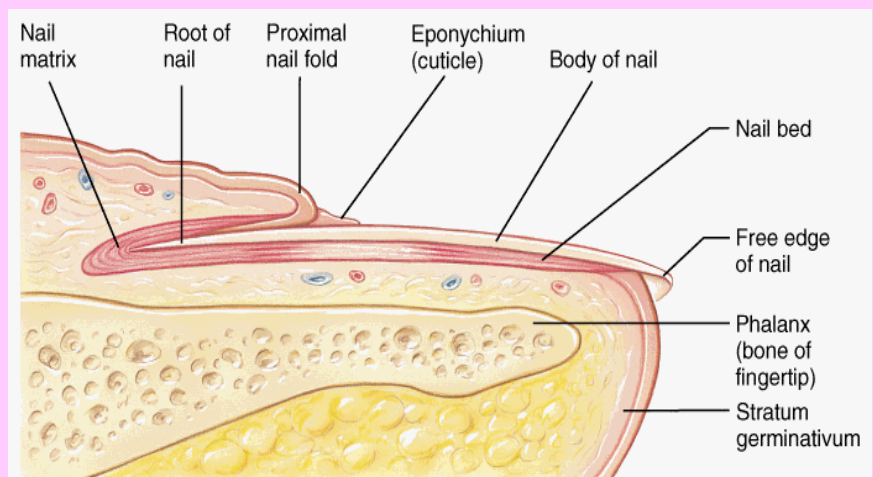
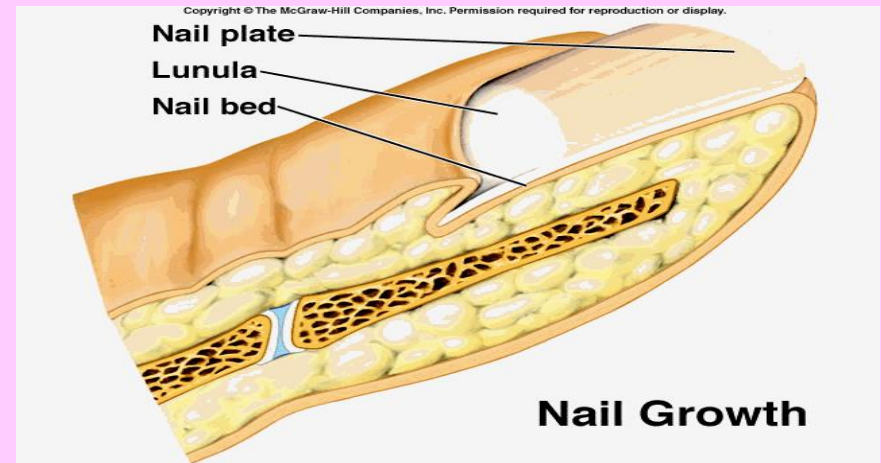


Nails – Indicators of Health

- **White nail bed or oval depressions**
 - Anemia
- **Pigmented spot not result of injury**
 - Melanoma
- **Horizontal furrows**
 - Period of serious illness or malnutrition
- **Extreme Curvature**
 - Certain disorders of lungs, heart, or liver
- **Red Streaks**
 - Rheumatoid arthritis, ulcers, or hypertension
- **Yellow**
 - Chronic respiratory disorders, thyroid disorders, or AIDS
- **Pitted and distorted**
 - Psoriasis
- **Blue or purple**
 - Lack of blood circulation

Nails - Parts

- Nail Root
 - Buried portion of the nail
- Nail Matrix
 - Deep to the nail root
 - Thickened proximal portion of the bed
 - where growth takes place
 - Cells push the nail forward

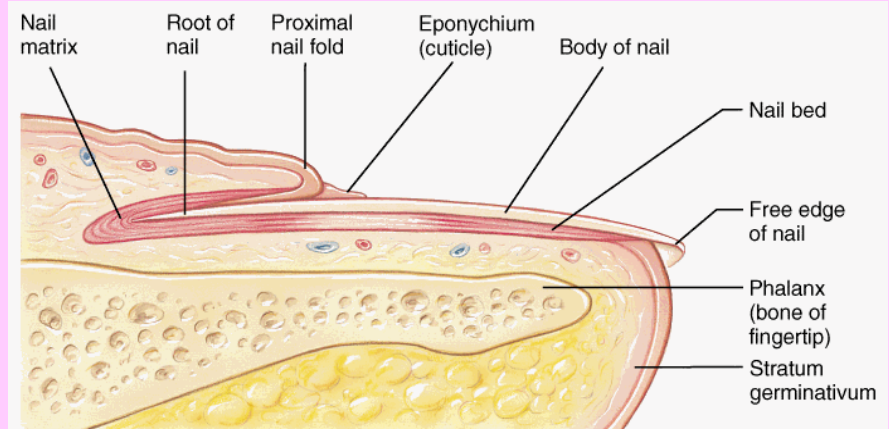
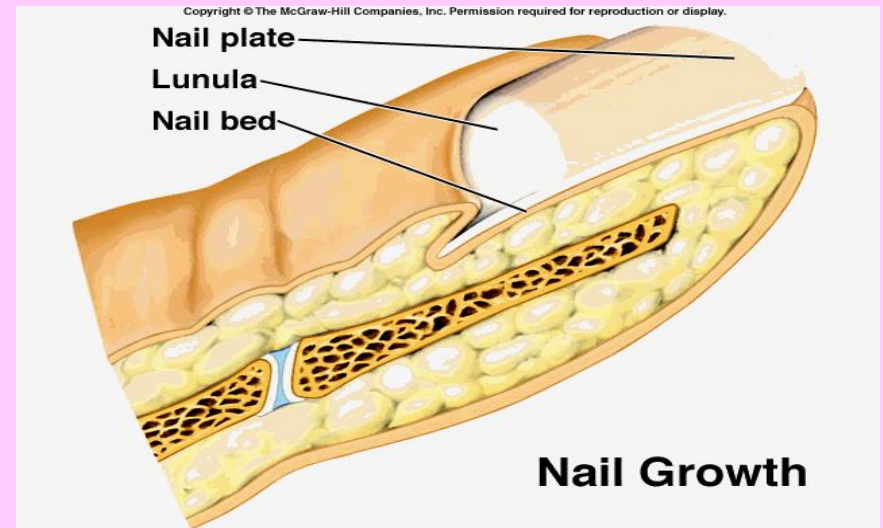


(b)

Copyright © 2001 Benjamin Cummings, an imprint of Addison Wesley Longman, Inc.

Nails - Parts

- **Body**
 - Visible, attached portion
 - Covers the nail bed
 - Appears pink because of blood flowing through underlying capillaries
- **Bed**
 - Under body
 - Deep layers of the epidermis

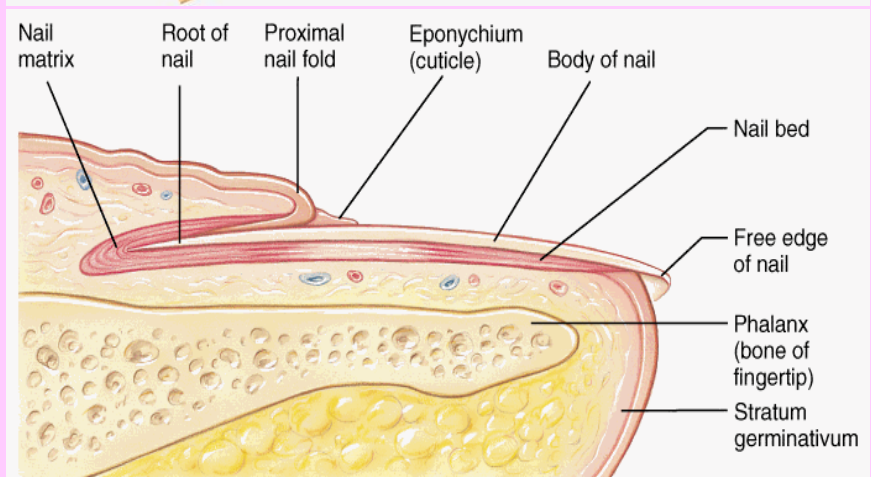
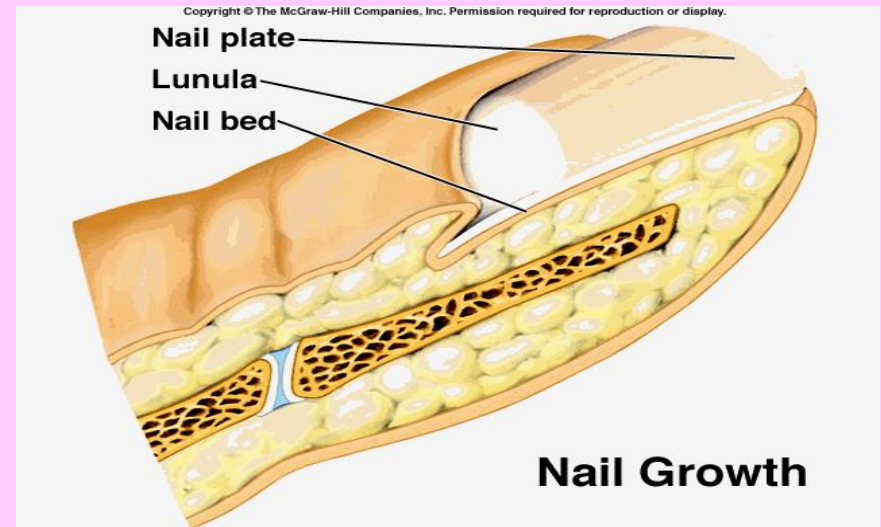


(b)

Copyright © 2001 Benjamin Cummings, an imprint of Addison Wesley Longman, Inc.

Nail Parts

- **Cuticle**
 - Eponychium
 - S. corneum of the nail root extends over the exposed nail
- **Lunula**
 - White crescent area
 - Appears whitish because the vascular tissue does not show through due to the thickened stratum basale in the area.

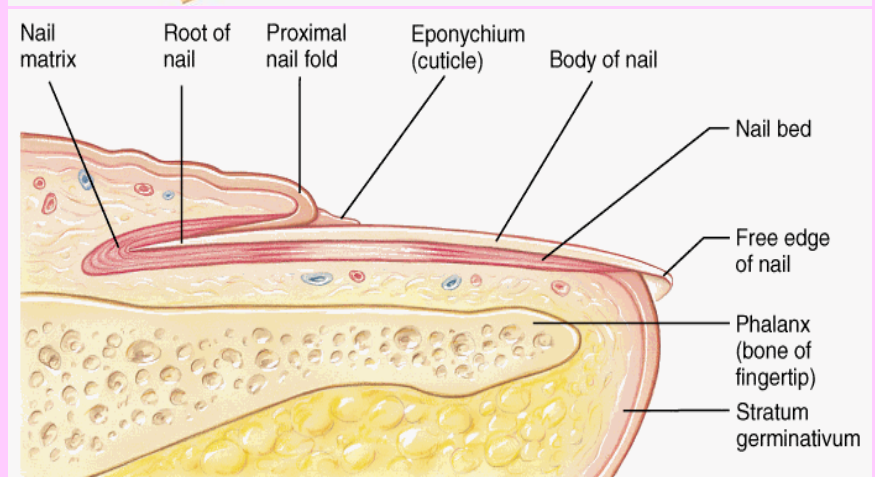
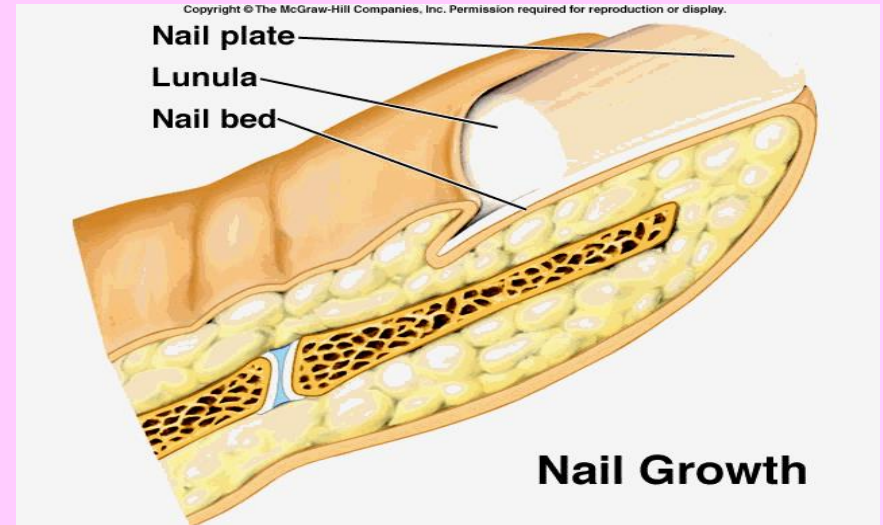


(b)

Copyright © 2001 Benjamin Cummings, an imprint of Addison Wesley Longman, Inc.

Nail Parts

- Free edge
 - Most distal edge; extends past finger edge
 - Appears white because there are no underlying capillaries
- Hyponychium
 - Aka. The quick
 - Beneath the free edge
 - Thickened region of the s. corneum, which secures the nail to the fingertip



(b)

Copyright © 2001 Benjamin Cummings, an imprint of Addison Wesley Longman, Inc.