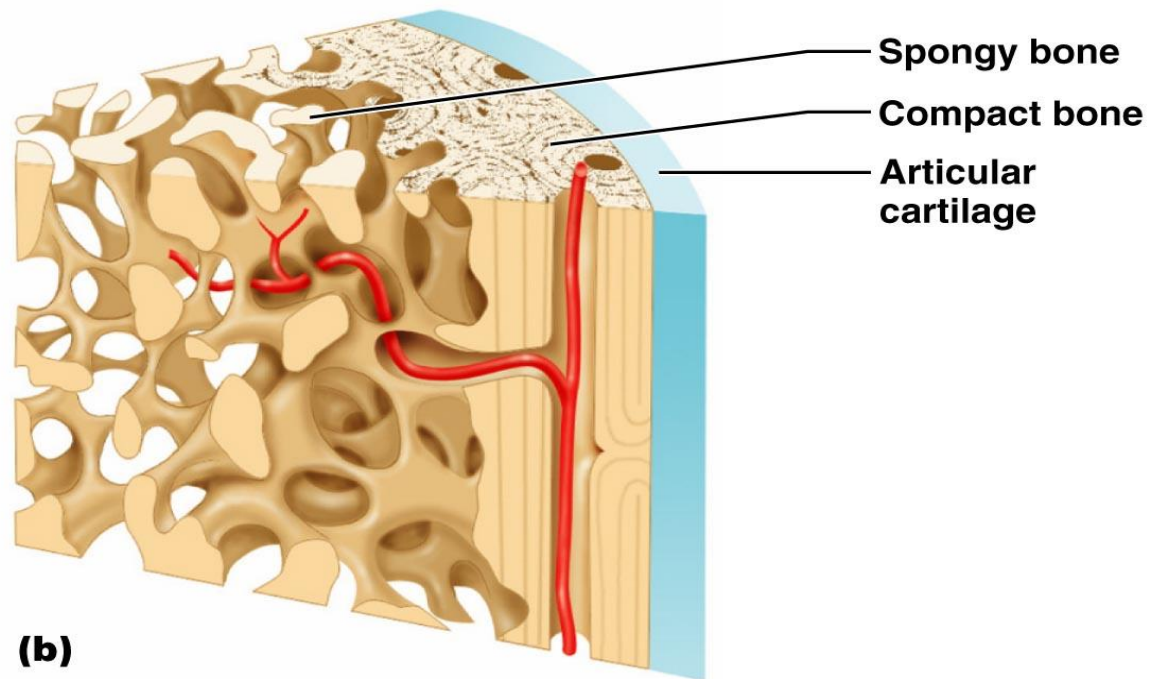


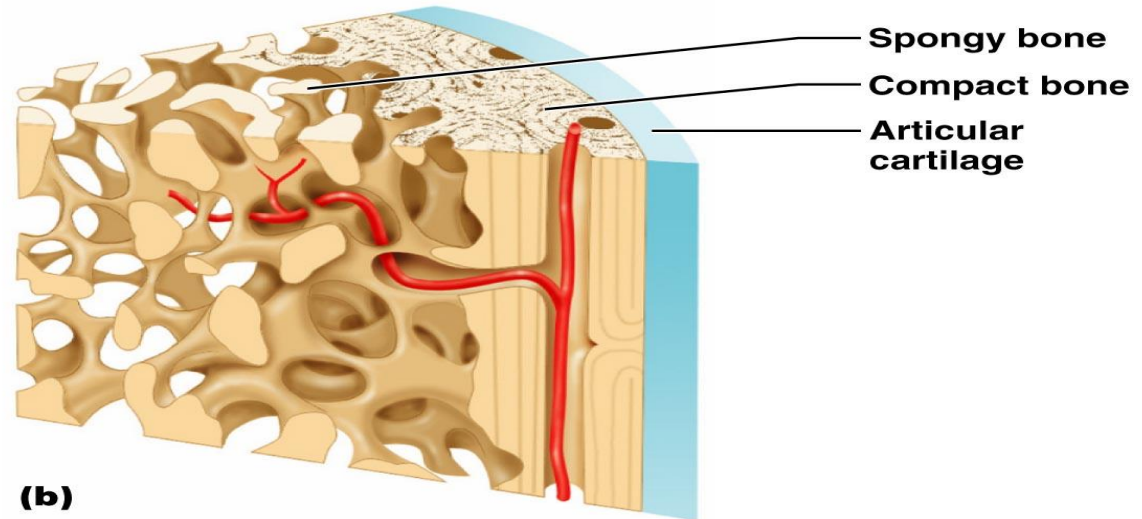
Chapter 6:
Bones and Skeletal Tissues
Bone Anatomy

Bone Textures

- Compact bone
 - Dense outer layer that looks smooth and solid



Bone Textures



Copyright © 2006 Pearson Education, Inc., publishing as Benjamin Cummings.

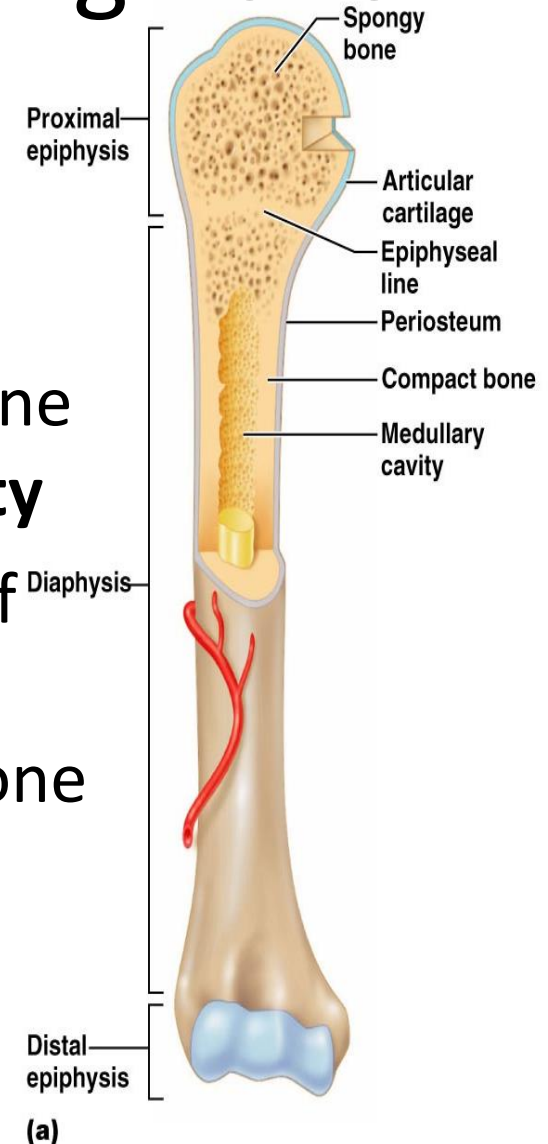
- Spongy Bone

- Cancellous bone
- Internal layer that looks like a honeycomb of small needle-like or flat pieces called **trabeculae**
- Open spaces are filled with red or yellow bone marrow

Structure of a Typical Long Bone

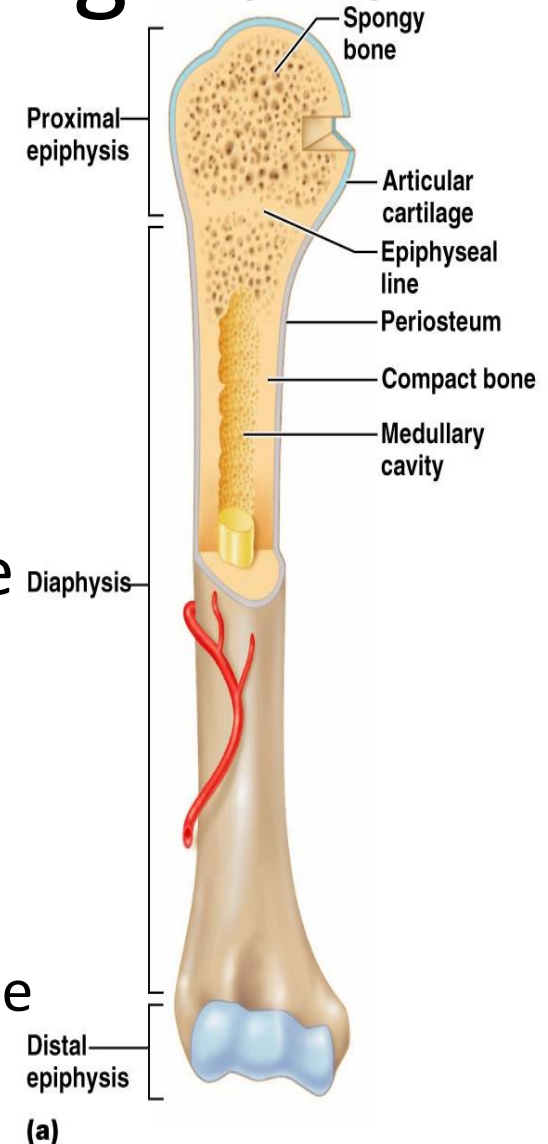
- Diaphysis

- Long axis of the bone
- Constructed of “thick” compact bone that surrounds the **medullary cavity**
- **Medullary cavity** – central cavity of the bone that contains fat (yellow marrow). Also called the yellow bone marrow cavity.

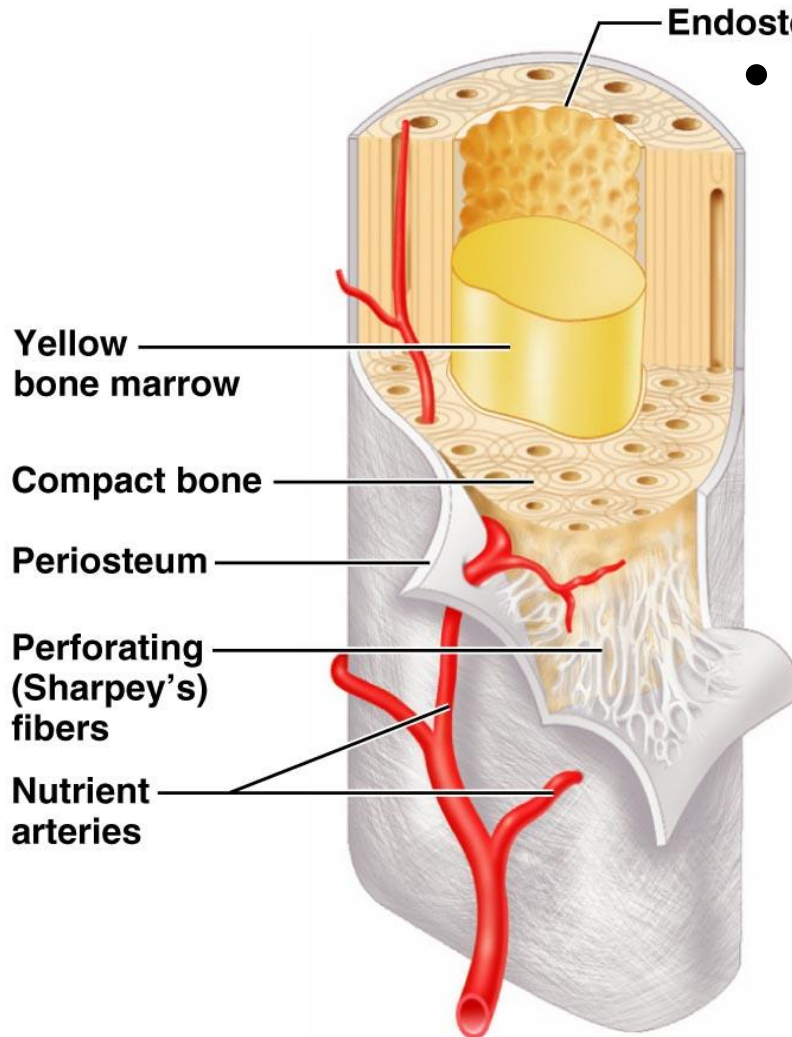


Structure of a Typical Long Bone

- Epiphyses
 - More expanded ends of bone
 - Exterior compact bone
 - Interior spongy bone
 - Joint surface covered with cartilage
 - Epiphyseal line – a remnant of the epiphyseal plate (growth plate)
 - A disc of hyaline cartilage that grows during childhood to lengthen the bone



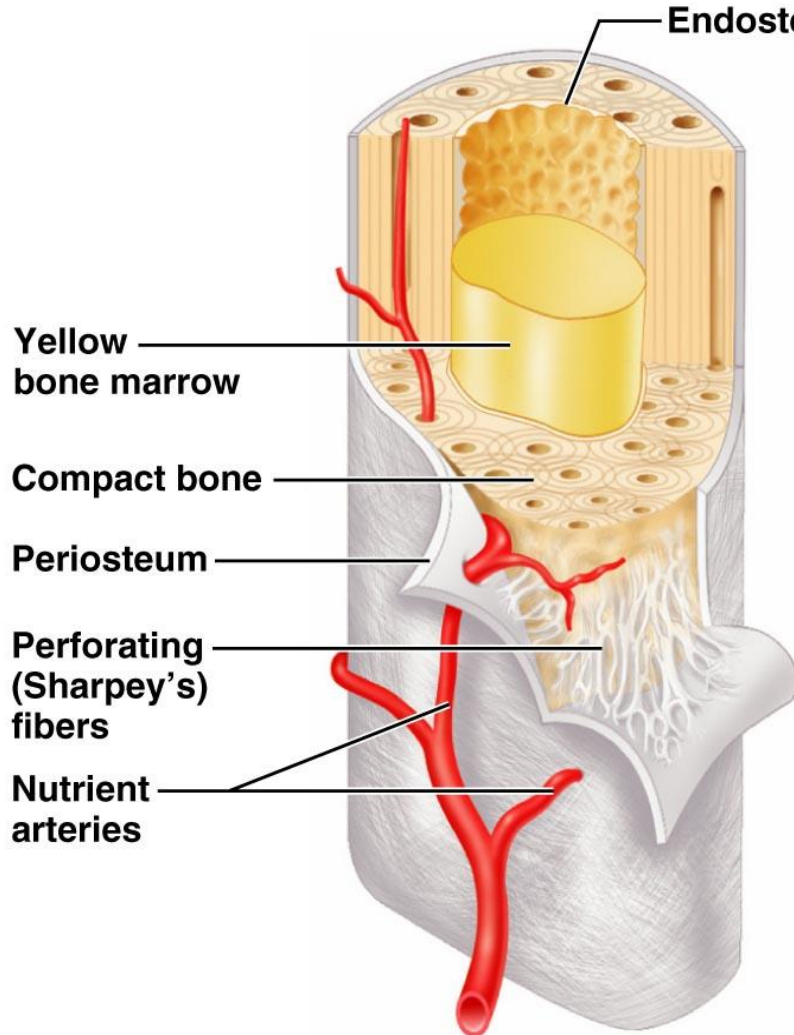
Structure of a Typical Long Bone



- Membranes

- Periosteum – double layered membrane that covers the outside of the bone
- Connected to bone by **Sharpey's fibers**
- Provides anchoring points for tendons and ligaments

Structure of a Typical Long Bone




- Membranes

- Endosteum

- Delicate connective tissue membrane that covers the internal surfaces of bone

Location of Hematopoietic Tissues



- Red marrow → makes **blood!!!**
- Typically found in the trabecular cavities of spongy bone of long bones and in diploë of flat bones → aka red marrow cavities
- In newborns, the medullary cavity of the diaphysis and all areas of spongy bone contain red marrow

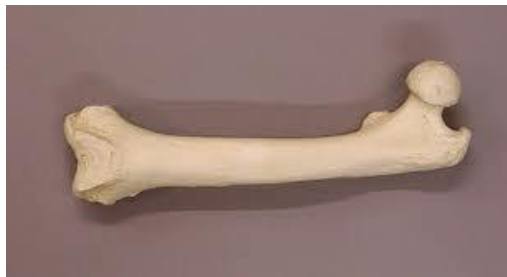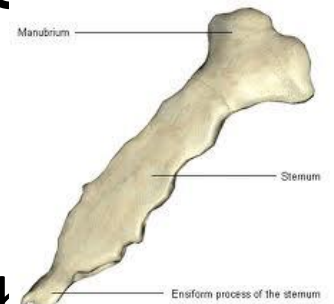
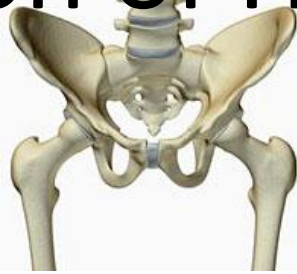Copyright © 2006 Pearson Education, Inc., publishing as Benjamin Cummings.



Location of Hematopoietic Tissues

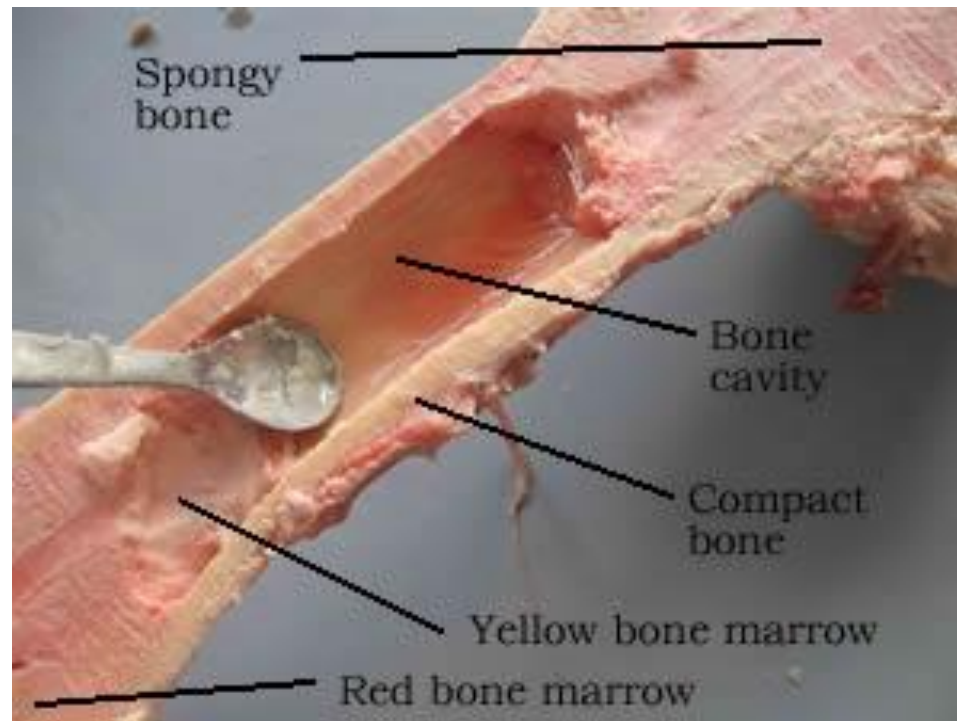
- Adults

- Yellow marrow extends well into the epiphyses, and little red marrow is present in spongy cavities.
- Only occurs in the heads of the femur and humerus (long bones)
- Red marrow is found in the diploe of flat bones (sternum) and some irregular bones (hip)



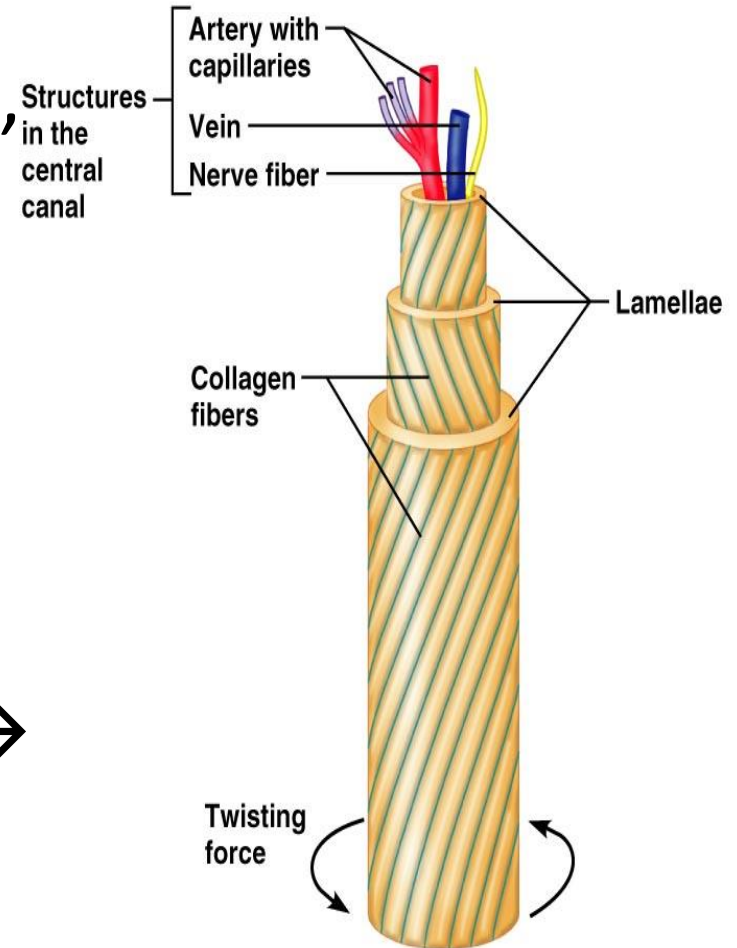
Location of Hematopoietic Tissues

- Yellow marrow can convert to red marrow if a person is highly anemic



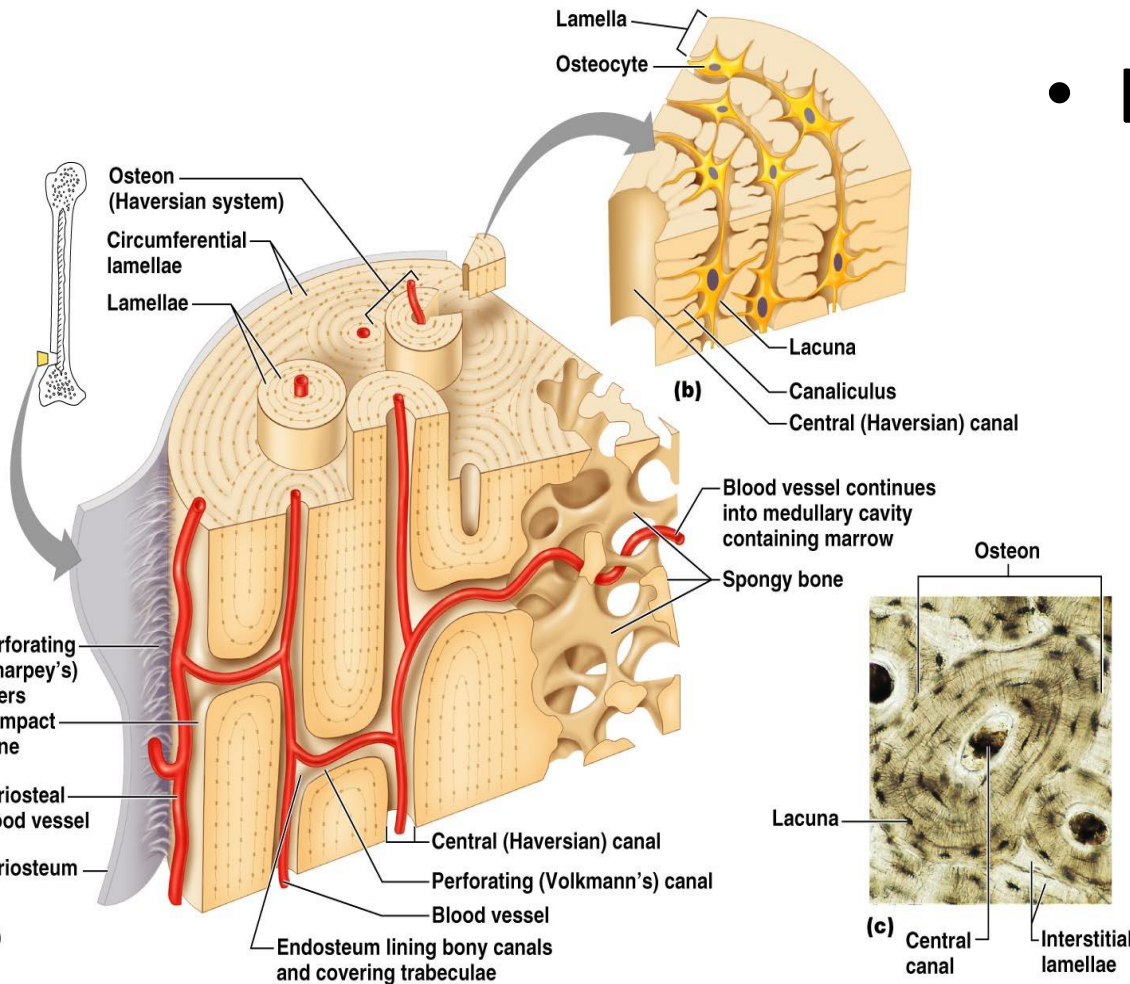
Microscopic Anatomy of Bone

- Bone looks dense and solid, but it is riddled with passageways!!
- Osteon (Haversian system)
 - Basic structural unit of compact bone
 - Tiny weight-bearing pillars → looks like growth rings of a tree trunk.

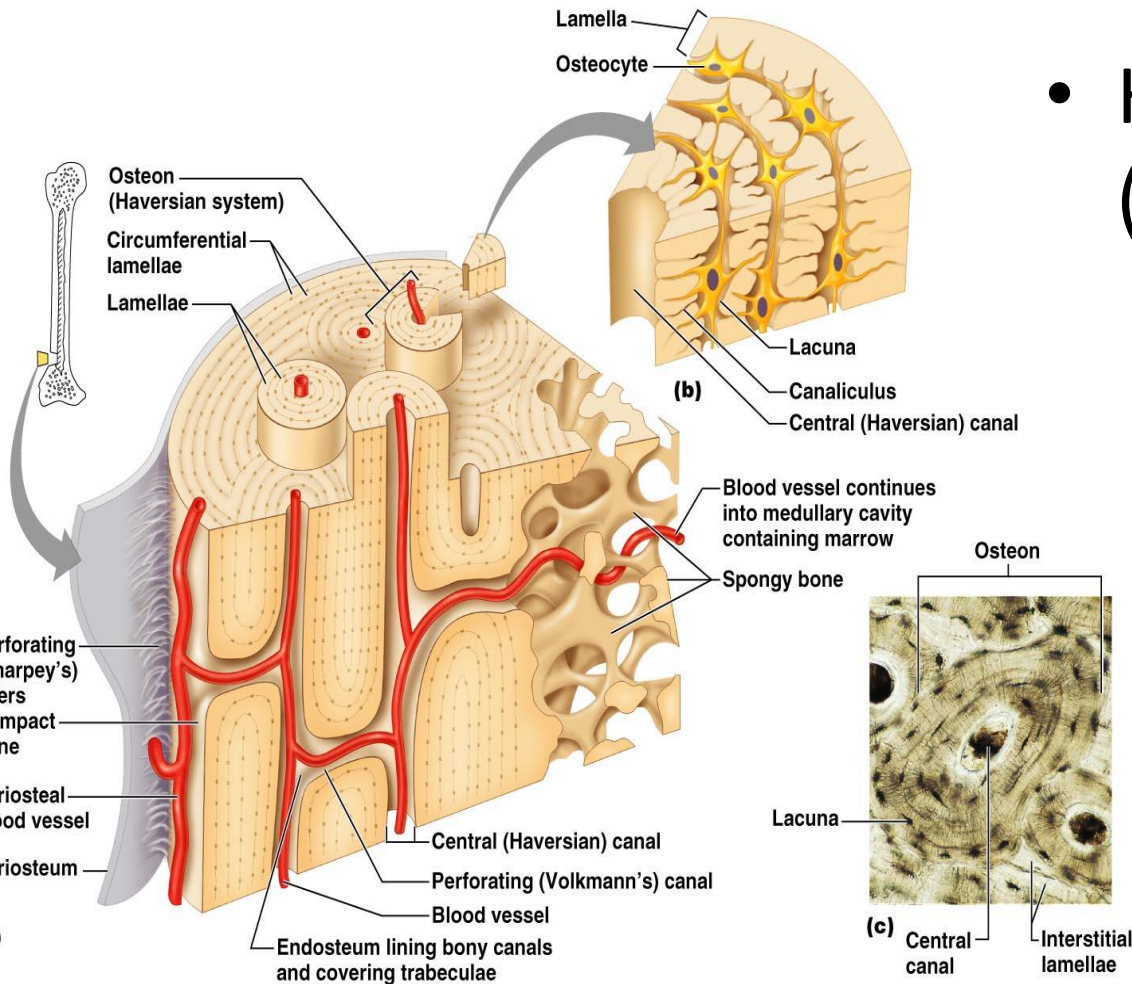


Microscopic Anatomy of Bone

- Lamella
 - One of the “growth rings”
 - Collagen fibers in adjacent lamella run in opposite directions → to withstand stresses!!

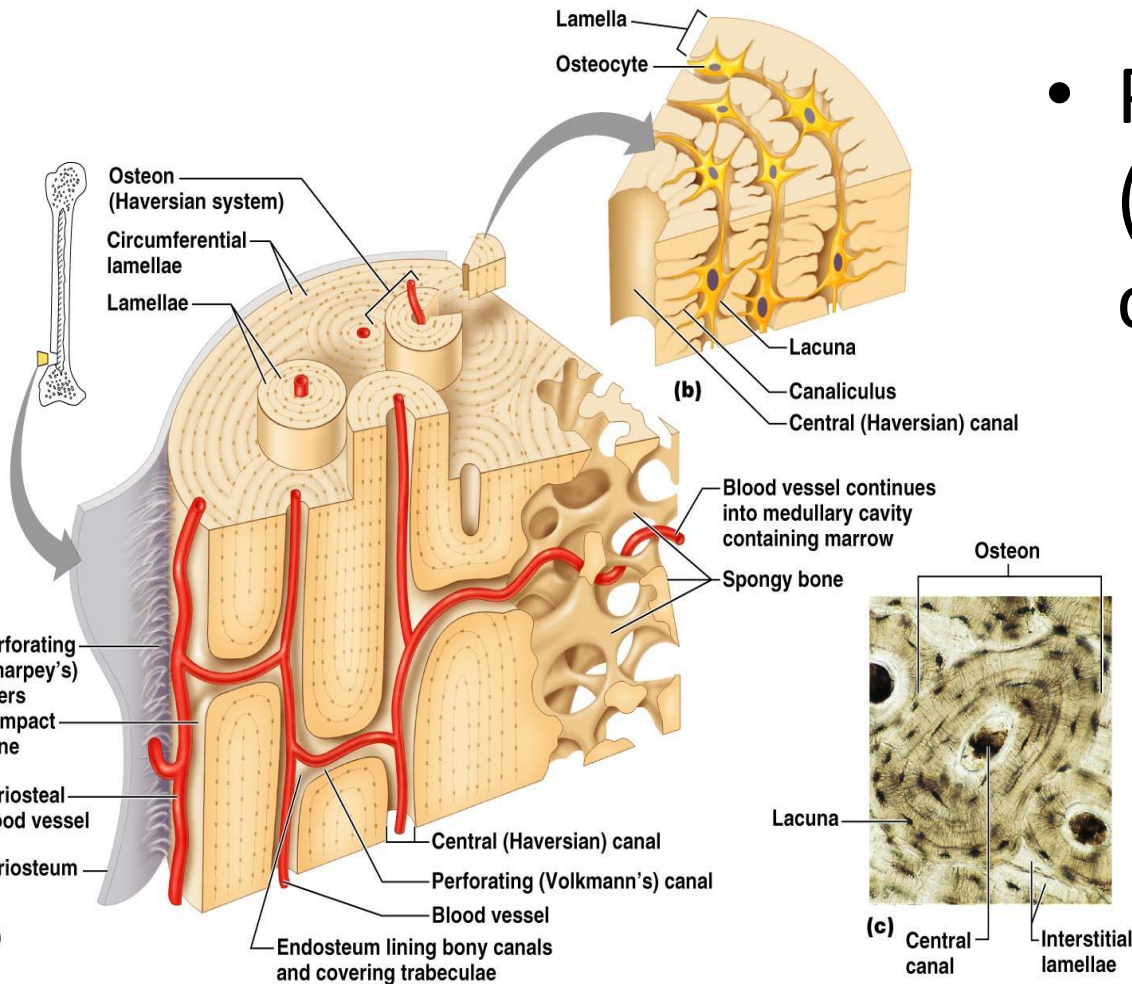


Microscopic Anatomy of Bone



- Haversian canal (Central canal)
 - Runs through the center of each osteon.
 - Contains blood vessels and nerve fibers

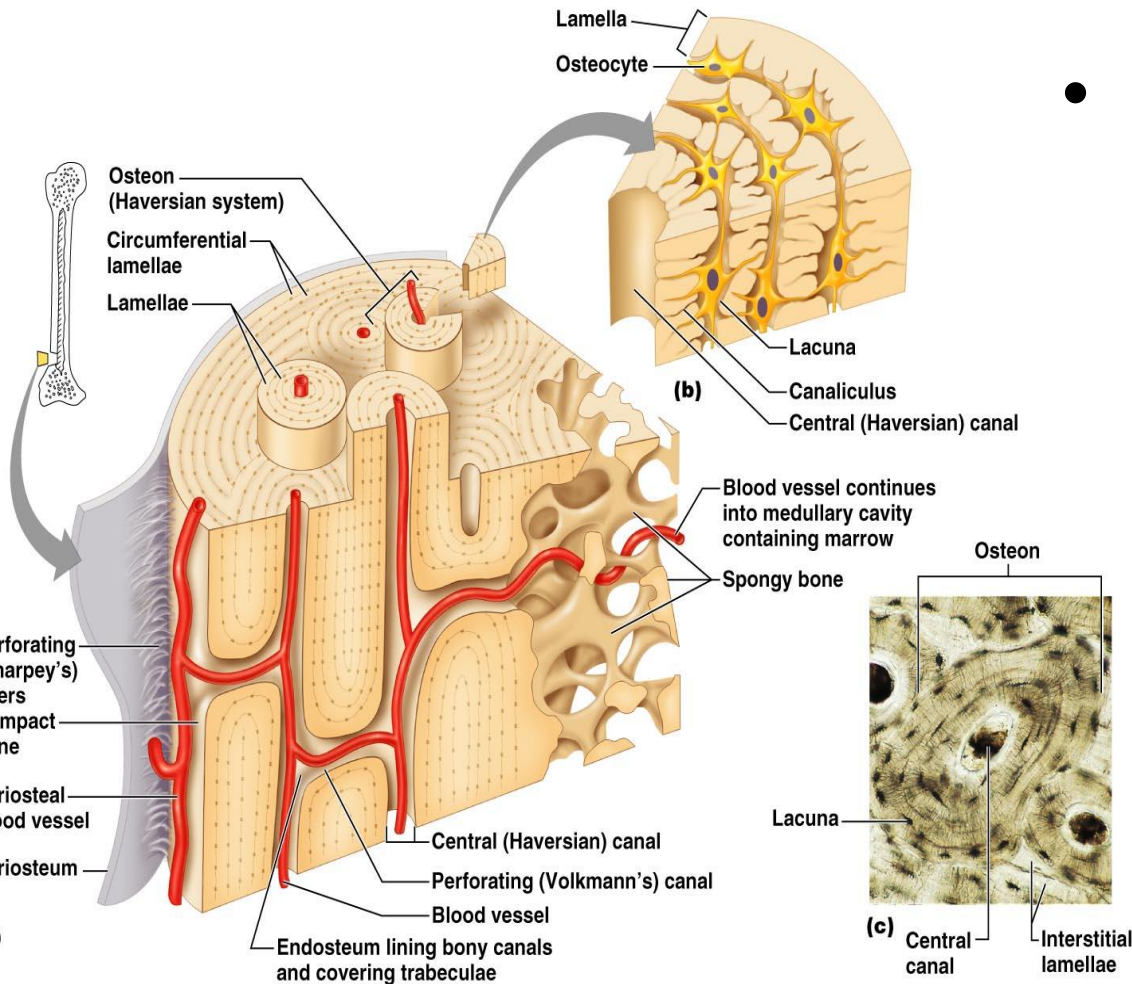
Microscopic Anatomy of Bone



- Perforating canals (Volkman's canals)
 - Lie at right angles and connect the blood and nerve supply of the entire bone

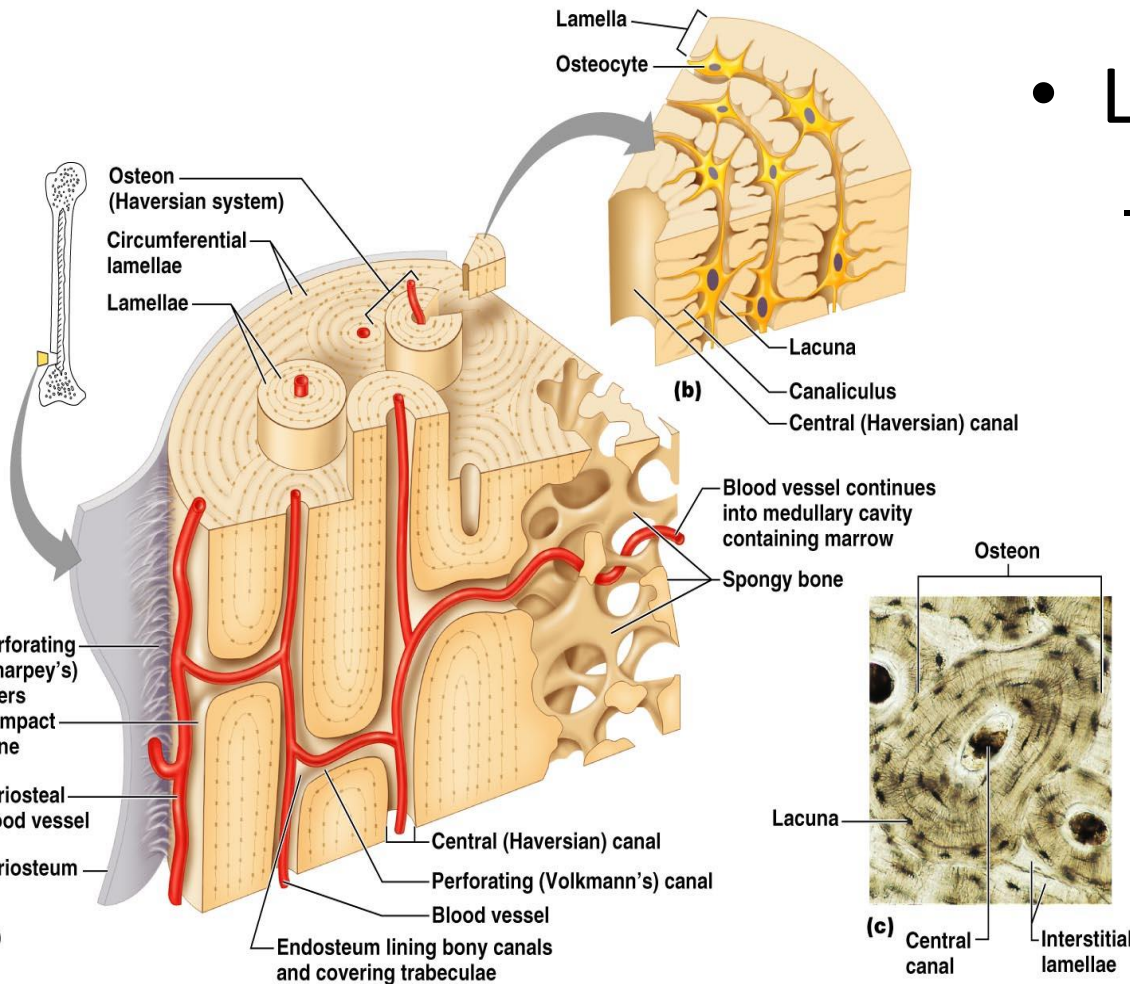
Microscopic Anatomy of Bone

- Osteocytes
 - Mature bone cells



Microscopic Anatomy of Bone

- Lacunae
 - Osteocytes reside here. Lie at the junctions of lamellae



Microscopic Anatomy of Bone

- Canaliculi
 - Hair-like canals that extend from the lacunae to each other

